

EMERGENCY MEDICINE PRACTICE

AN EVIDENCE-BASED APPROACH TO EMERGENCY MEDICINE

Ankle Injuries In The ED: How To Provide Rapid And Cost-Effective Assessment And Treatment

May 2002
Volume 4, Number 5

5:23 p.m.: A 5-year-old boy presents with a swollen ankle after jumping off of the monkey bars at school. The ankle is only slightly swollen and tender, and the films are normal. This ankle sprain gets an Ace wrap and goes home. You think, "I wish all my cases were this simple."

6:18 p.m.: A 50-year-old "weekend warrior" everted his right ankle sliding into home. While the ankle is swollen, the x-ray only shows an avulsion of the medial malleolus. Another "slam dunk"—you discharge the patient home with a posterior splint and a diagnosis of chip fracture.

These two cases seen within the hour have one thing in common: In each, the diagnosis and treatment are wrong.

HARDLY a shift goes by when the emergency physician does not see at least one ankle injury. Despite its pedestrian status, ankle injuries have the potential for significant morbidity. The emergency physician must be expert in the evaluation, diagnosis, and management of acute ankle injuries while also remaining time- and cost-effective. This issue of *Emergency Medicine Practice* provides a review of ankle anatomy, biomechanics of the ankle joint, and an update on diagnostic and management approaches to acute ankle injuries.

*"Always read stuff that will make you look good if you die in the middle of it."
—P. J. O'Rourke*

Epidemiology

Each year in the United States, ankle injuries account for as many as 4%-12% of ED visits and an estimated cost ranging from \$500 million to

Authors

Eric Wasserman, MD

Clinical Instructor, Department of Emergency Medicine, Mount Sinai School of Medicine, New York, NY; Attending Physician, Department of Emergency Medicine, Jersey City Medical Center, Jersey City, NJ.

Scot Hill, MD

Assistant Clinical Professor, Department of Emergency Medicine, Mount Sinai School of Medicine, New York, NY.

Peer Reviewers

Michael D. Burg, MD

Assistant Clinical Professor, UCSF—Fresno, University Medical Center, Emergency Department, Fresno, CA.

Michael A. Turturro, MD, FACEP

Vice Chair and Director of Academic Affairs, Department of Emergency Medicine, The Mercy Hospital of Pittsburgh; Clinical Associate Professor of Emergency Medicine, University of Pittsburgh School of Medicine, Pittsburgh, PA.

CME Objectives

Upon completing this article, you should be able to:

1. predict specific injury patterns based on directional forces that occur at the moment of loading;
2. perform a complete physical examination of the ankle and test for specific injuries utilizing provocative maneuvers;
3. list evidence-based criteria for ordering ankle x-rays;
4. classify ankle fractures based on mechanism of injury and anatomic location of the fracture site; and
5. differentiate between stable and unstable injury patterns and develop appropriate management strategies for each.

Date of original release: May 1, 2002.

Date of most recent review: April 4, 2002.

See "Physician CME Information" on back page.

Editor-in-Chief

Stephen A. Colucciello, MD, FACEP, Assistant Chair, Department of Emergency Medicine, Carolinas Medical Center, Charlotte, NC; Associate Clinical Professor, Department of Emergency Medicine, University of North Carolina at Chapel Hill, Chapel Hill, NC.

Associate Editor

Andy Jagoda, MD, FACEP, Professor of Emergency Medicine; Director, International Studies Program, Mount Sinai School of Medicine, New York, NY.

Editorial Board

Judith C. Brillman, MD, Residency Director, Associate Professor, Department of Emergency Medicine, The University of New Mexico Health Sciences

Center School of Medicine, Albuquerque, NM.

W. Richard Bukata, MD, Assistant Clinical Professor, Emergency Medicine, Los Angeles County/USC Medical Center, Los Angeles, CA; Medical Director, Emergency Department, San Gabriel Valley Medical Center, San Gabriel, CA.

Francis M. Fesmire, MD, FACEP, Director, Chest Pain—Stroke Center, Erlanger Medical Center; Assistant Professor of Medicine, UT College of Medicine, Chattanooga, TN.

Valerio Gai, MD, Professor and Chair, Department of Emergency Medicine, University of Turin, Italy.

Michael J. Gerardi, MD, FACEP, Clinical Assistant Professor, Medicine, University of Medicine and Dentistry of New Jersey; Director, Pediatric Emergency Medicine, Children's Medical Center, Atlantic Health System; Vice-Chairman, Department of

Emergency Medicine, Morristown Memorial Hospital.

Michael A. Gibbs, MD, FACEP, Residency Program Director; Medical Director, MedCenter Air, Department of Emergency Medicine, Carolinas Medical Center; Associate Professor of Emergency Medicine, University of North Carolina at Chapel Hill, Chapel Hill, NC.

Gregory L. Henry, MD, FACEP, CEO, Medical Practice Risk Assessment, Inc., Ann Arbor, MI; Clinical Professor, Department of Emergency Medicine, University of Michigan Medical School, Ann Arbor, MI; President, American Physicians Assurance Society, Ltd., Bridgetown, Barbados, West Indies; Past President, ACEP.

Jerome R. Hoffman, MA, MD, FACEP, Professor of Medicine/Emergency Medicine, UCLA School of Medicine; Attending Physician, UCLA Emergency Medicine Center;

Co-Director, The Doctoring Program, UCLA School of Medicine, Los Angeles, CA.

John A. Marx, MD, Chair and Chief, Department of Emergency Medicine, Carolinas Medical Center, Charlotte, NC; Clinical Professor, Department of Emergency Medicine, University of North Carolina at Chapel Hill, Chapel Hill, NC.

Michael S. Radeos, MD, MPH, Attending Physician, Department of Emergency Medicine, Lincoln Medical and Mental Health Center, Bronx, NY; Assistant Professor in Emergency Medicine, Weill College of Medicine, Cornell University, New York, NY.

Steven G. Rothrock, MD, FACEP, FAAP, Associate Professor of Emergency Medicine, University of Florida; Orlando Regional Medical Center; Medical Director of Orange County Emergency

Medical Service, Orlando, FL.

Alfred Sacchetti, MD, FACEP, Research Director, Our Lady of Lourdes Medical Center, Camden, NJ; Assistant Clinical Professor of Emergency Medicine, Thomas Jefferson University, Philadelphia, PA.

Corey M. Slovis, MD, FACP, FACEP, Professor of Emergency Medicine and Chairman, Department of Emergency Medicine, Vanderbilt University Medical Center; Medical Director, Metro Nashville EMS, Nashville, TN.

Mark Smith, MD, Chairman, Department of Emergency Medicine, Washington Hospital Center, Washington, DC.

Charles Stewart, MD, FACEP, Colorado Springs, CO.

Thomas E. Terndrup, MD, Professor and Chair, Department of Emergency Medicine, University of Alabama at Birmingham, Birmingham, AL.

more than \$2 billion.¹⁻⁴ Some hospitals see an average of six patients with ankle injuries per day.¹ Following one 1994 winter ice storm in Indianapolis, ankle injuries accounted for more than 15% of the ED volume.⁵

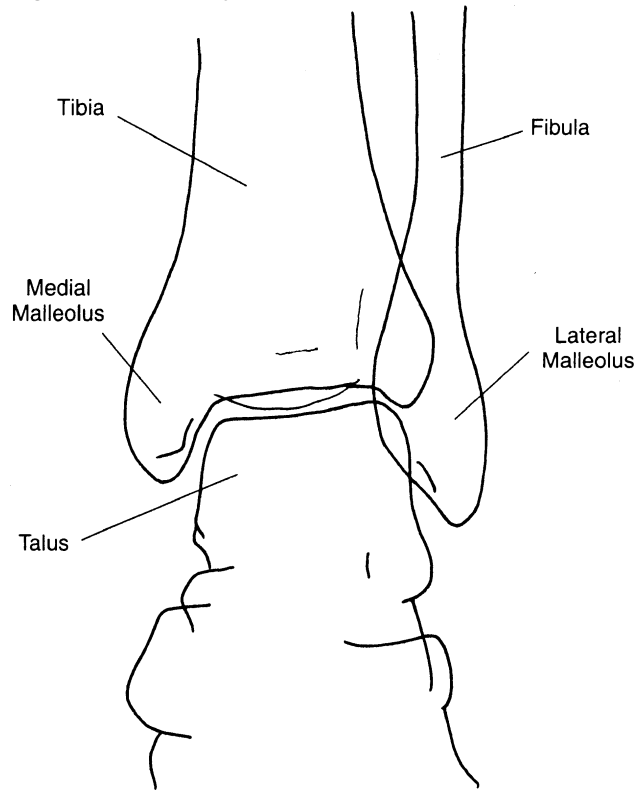
Athletes injure their ankles more frequently than any other body part.⁶⁻⁸ Certain sports are associated with specific injuries. Snowboarders commonly fracture the lateral process of the talus,⁸ while skiers often break the tibia and fibula.⁹ Football is associated with syndesmosis sprains,¹⁰ and basketball is associated with lateral sprains.¹¹ Dancers are susceptible to several injuries, including stress fractures, ankle impingement, and tendon dysfunction.^{12,13} Pilon fractures (distal tibial metaphysis fracture with disruption of the talar dome) are common in motor vehicle collisions and falls from a height.¹⁴

“If the waitress has dirty ankles, the chili should be good.”—Al McGuire, U.S. collegiate basketball coach¹⁵

Functional Anatomy

The ankle joint (or, more pedantically, the talocrural joint) is the articulation between the tibia, fibula, and talus. It is a synovial-type joint that permits movement predominantly in the sagittal plane. This “hinge”-type

Figure 1. The ankle joint, anteroposterior view.



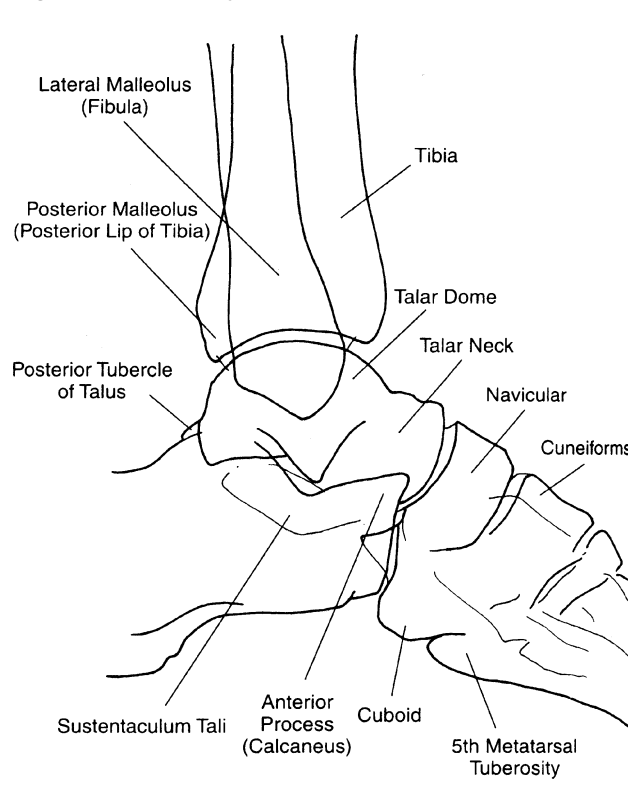
Reproduced with permission from: Williamson B, Schwartz DT. The ankle and leg. In: Schwartz DT, Reisdorff EJ, eds. *Emergency Radiology*. New York: McGraw-Hill; 2000:160. Figure 9-5b.

joint allows approximately 20° of dorsiflexion, 30°-50° of plantar flexion, and roughly 25° of inversion-eversion in normal subjects.^{16,17} This complex motion is achieved by a relatively simple arrangement of bone, articular cartilage, synovial fluid, ligaments, and tendons.

Bones

The dome of the talus (trochlea) sits in the mortise, a socket created by the distal articulation of the tibia and fibula. Bony prominences (termed malleoli) form the medial and lateral aspects of the mortise, respectively, and the inferior end of the tibia (plafond) forms its roof. (See Figure 1.) There is also an anterior and posterior lip of the distal tibia, the latter of which is termed the posterior malleolus. The mortise is wider anteriorly than posteriorly and is concave from anterior to posterior, providing a snug fit for the talus. The talar convexity accounts for the characteristic semi-circular appearance on a lateral film of the ankle. (See Figure 2.) During ankle dorsiflexion, the talus rocks posteriorly, presenting the breadth of the talar dome to the articular surface of the tibial plafond, thus stabilizing the joint.⁴ There is also an articulation between the distal ends of the tibia and fibula (distal tibiofibular joint) that stabilizes the mortise by limiting translation between the two bones.

Figure 2. The ankle joint, lateral view.



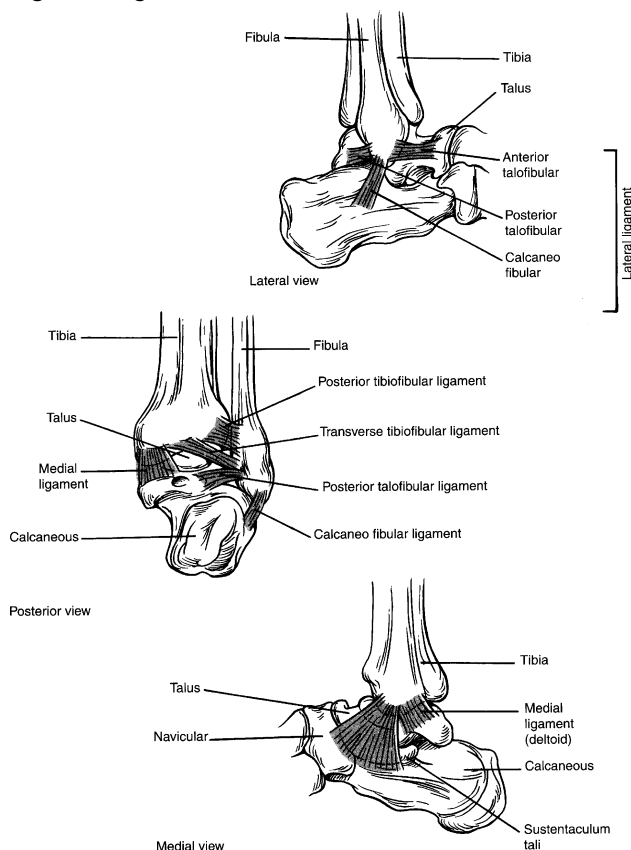
Reproduced with permission from: Williamson B, Schwartz DT. The ankle and leg. In: Schwartz DT, Reisdorff EJ, eds. *Emergency Radiology*. New York: McGraw-Hill; 2000:160. Figure 9-5d.

Adduction, abduction, internal rotation, external rotation, dorsiflexion, and plantar flexion describe the *motion of the talus* within the mortise. Adduction and abduction are synonymous with inversion and eversion, respectively; these motions occur when the talus rotates either inward (adduction) or outward (abduction) around the long axis of the *foot*. Internal and external rotation occur when the talus rotates either inward (internal rotation) or outward (external rotation) around the long axis of the *leg*. Dorsiflexion and plantar flexion occur as the talus rocks either posteriorly (dorsiflexion) or anteriorly (plantar flexion) within the mortise. Supination and pronation describe the *position of the foot* with respect to the ankle and involve some degree of motion at the subtalar joint. To achieve these positions, the foot rotates either inward (supination) or outward (pronation) around its long axis. When the foot is supinated, injuries begin anteriorly or laterally and progress to involve medial ankle structures; conversely, when the foot is pronated, medial ankle structures are injured first, followed by more lateral structures.¹⁸

Ligaments

The talocrural ligaments provide stability to the ankle

Figure 3. Ligaments of the ankle.



Reproduced with permission from: Michael JA, Steill IG. Ankle injuries. In: Tintinalli JE, Kelen GD, Stapczynski JS, eds. *Emergency Medicine: A Comprehensive Study Guide*. New York: McGraw-Hill; 2000:1826. Figure 268-1.

joint. Three groups of ligaments connect the ankle bones on all four sides, forming a ring. The deltoid or medial collateral ligament stabilizes the joint medially, the lateral collateral ligaments steady the joint laterally, and the syndesmotomic ligaments maintain anterior and posterior alignment. (See Figure 3.)

Anatomic stability depends on the number and location of breaks in the ring. A single break in the ring (isolated ligament rupture or nondisplaced single malleolar fracture) is usually a stable injury. *More than one break (of either a ligament or bone) involving opposite sides of the ring disrupts the proper anatomic and functional relationship of the talus within the mortise and results in an unstable injury.* Unstable injuries include such patterns as a lateral ligament tear and medial malleolar fracture or bimalleolar fractures.

Lateral Collateral Ligaments

Injuries to the lateral collateral ligaments are responsible for 85% of acute ankle sprains,¹⁹ particularly in sports.^{20,21} This ligament complex limits inversion (adduction) of the talus and prevents its anterior and lateral subluxation. Injury typically occurs during forceful inversion, which stretches the individual ligaments to the point of complete or partial rupture. Alternatively, the ligament remains intact and avulses a bony fragment from the distal fibula. The individual ligaments that comprise the lateral group are the anterior talofibular ligament (ATFL), posterior talofibular ligament (PTFL), and calcaneofibular ligament (CFL). The ATFL prevents anterior subluxation of the talus and is the weakest of the three lateral ligaments. *It is the most frequently injured ligament of the ankle.*^{16,22,23} Although isolated lateral ligament tears are common, be aware that a concomitant injury to the medial side is possible and would indicate an unstable injury.

Medial Collateral Ligaments

The deltoid (medial) ligament is a primary stabilizer of the ankle joint.²⁴ This group of ligaments is 20%-50% stronger than the lateral group²⁰ and is rarely injured in isolation. It limits eversion (abduction) and external rotation, and it prevents talar subluxation. Injury typically occurs through a mechanism of forced eversion. Deltoid ligament tears occur concomitantly with medial malleolar fractures, fibular fractures, and sprains of the lateral ligaments or syndesmosis. When the deltoid ligament is damaged, the emergency physician should search carefully for other injuries.

Syndesmotomic Ligaments

The ankle syndesmosis, or distal tibiofibular joint, is comprised of several ligaments that limit translation or displacement of the fibula relative to the tibia and preserve the correct anatomic and functional relationship of the talar dome within the mortise. These ligaments are the anterior inferior tibiofibular ligament

(AITFL), posterior inferior tibiofibular ligament (PITFL), transverse tibiofibular ligament (TTFL) and interosseous ligament (IOL). Although not nearly as common as lateral ligamentous injuries, associated injury to the tibiofibular syndesmosis can result in prolonged impairment.²⁵ A mechanism of forceful dorsiflexion or external rotation of the ankle is responsible for the majority of these injuries.^{2,23,25}

Tendons

The peroneal muscles of the lateral crural compartment contribute to foot eversion and plantar flexion and give rise to the longus and brevis tendons just above the ankle. Sudden forced dorsiflexion of the foot typically produces injuries to the peroneal tendons or their bony attachments. As the retinaculum tears away and strips bone from the distal fibula, injuries range from subluxation or dislocation to avulsion fractures.²⁶ The tibialis posterior muscle of the posterior crural compartment contributes to foot inversion and plantar flexion and gives rise to the tibialis posterior tendon above the ankle.

The Achilles tendon, or tendo calcaneus, arises from the gastrocnemius and soleus muscles of the calf and inserts on the calcaneus. It is the main plantar flexor of the foot. The Achilles tendon can rupture when abrupt dorsiflexion overstretches the tendon, as often happens during sports.²⁷ Spontaneous rupture may occur in older patients with underlying medical conditions (rheumatoid arthritis, gout, or hyperparathyroidism), those taking fluoroquinolones, or individuals who have had prior steroid injections around the tendon.^{28,29}

"It's tough to make predictions, especially about the future."—Yogi Berra, U.S. baseball player and manager³⁰

Biomechanics Of Injury

For practical purposes, ankle injuries can be divided into three groups based on the motion of the talus within the mortise:

- Inversion (adduction)
- Eversion (abduction)
- External rotation

The patterns of injury that occur during inversion and eversion share a reciprocal relationship. Each features damage to the ipsilateral ligament (with or without a transverse avulsion fracture of the malleolus) and an oblique impaction fracture of the opposite malleolus.

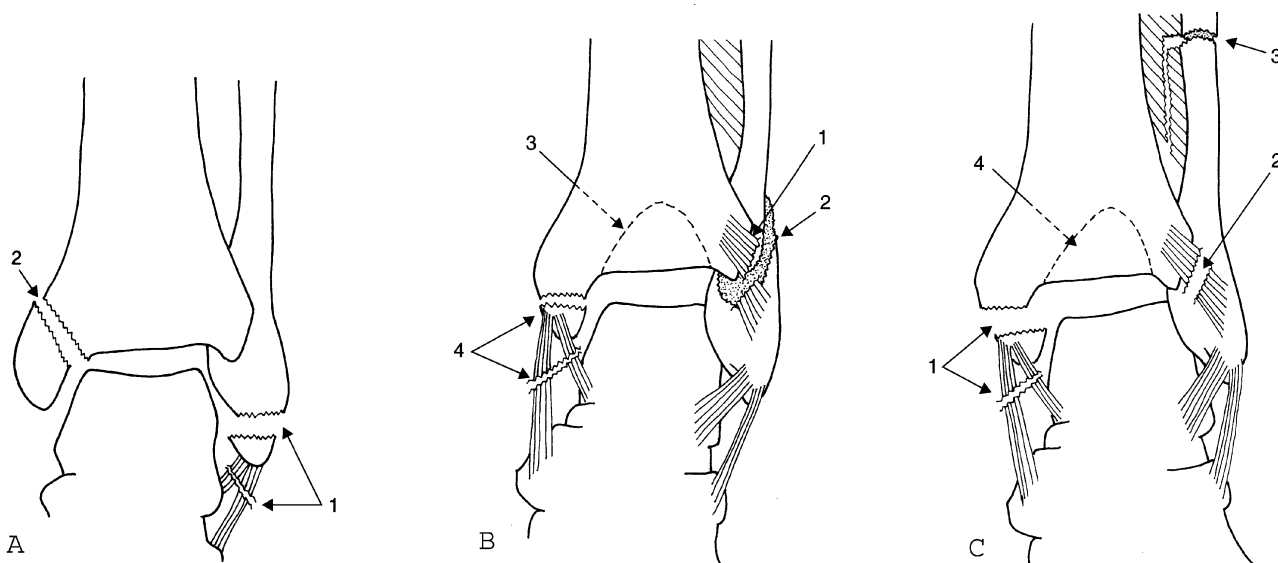
Inversion

When the ankle is inverted, the foot is supinated and the talus is adducted. Inversion or supination-adduction (SA) forces injure lateral ankle structures first and progress medially.³¹ These forces: 1) tear the lateral ligaments or avulse a bony fragment from the lateral malleolus; and 2) drive the talar dome medially, impacting and obliquely fracturing the medial malleolus *at* the level of the mortise. (See Figure 4a.) The syndesmosis usually remains intact during forceful inversion.

Eversion

In contrast, when the ankle is everted, the foot is

Figure 4. Biomechanics of injury: A) supination-adduction or inversion; B) supination-external rotation; C) pronation-external rotation. According to the Lauge-Hansen classification system of ankle fractures, the numbers represent the order in which specific structures are injured.



Reproduced with permission from: Williamson B, Schwartz DT. The ankle and leg. In: Schwartz DT, Reisdorff EJ, eds. *Emergency Radiology*. New York: McGraw-Hill; 2000:167. Figure 9-10.

pronated and the talus is abducted. Eversion or pronation-abduction (PA) forces injure medial structures first, 1) tearing the deltoid ligament or avulsing a fragment from the medial malleolus; 2) rupturing the syndesmosis; and 3) driving the talar dome laterally, causing an oblique fracture of the lateral malleolus *at* the level of the mortise.

External Rotation

When the talus is externally rotated, the foot is either supinated or pronated. The rotational or torsional forces that are introduced create a clockwise or counterclockwise pattern of injury around the long axis of the leg.

Supination-external (SE) rotation forces injure anterolateral ankle structures first, beginning with: 1) rupture of the anterior syndesmosis; 2) spiral fracture of the fibula *at* the level of the mortise; 3) posterior malleolar fracture and/or posterior syndesmotic tear; and, finally, 4) medial malleolar fracture and/or deltoid ligament sprain. (See Figure 4b.)

In contrast, pronation-external (PE) rotation forces injure medial ankle structures first, beginning with: 1) medial malleolar fracture and/or deltoid ligament tear; and progressing to 2) tear of the anterior syndesmosis; 3) fibular shaft fracture *above* the level of the mortise; and, finally, 4) posterior syndesmosis tear. (See Figure 4c.)

Differential Diagnosis

The emergency physician should understand two important concepts in the differential diagnosis of ankle injuries:

1. With the exception of lateral ligament tears and lateral malleolar avulsions, *injuries do not often occur in isolation*. The emergency physician must carefully evaluate the integrity of the mortise in a search for concomitant injuries or instability. These injuries often involve the opposite side of the ankle, the mid or proximal foot, and the proximal fibula.
2. The level of the fibular fracture with respect to the mortise determines overall joint stability and guides management. *Fibular fractures that occur at or above the level of the mortise are almost always associated with rupture of the syndesmosis and create an unstable injury*. Fractures *below* the mortise are usually stable, unless other injuries that disrupt the ring are also present.

Dupuytren Fracture

This is a fibular shaft fracture located 4-10 cm above the mortise that occurs during a combination of forceful eversion and external rotation. Since the syndesmosis ruptures distal to the fracture, the mortise is destabilized.³² Other associated injuries may include fracture of the medial or posterior malleolus and deltoid ligament tear. Patients are unable to bear

weight and exhibit tenderness of the supramalleolar fibula. Beware that the fibular fracture may lie above the visible edge of the ankle film. One radiographic clue is a widened medial clear space (talar shift) on the AP ankle view. If a Dupuytren fracture is suspected based on history, physical examination, or routine ankle series, order dedicated leg films.

Maisonneuve Fracture

This spiral fracture of the proximal fibula is similar to the Dupuytren fracture in that it occurs during external rotation of the talus and disrupts the syndesmosis. These highly unstable injuries are often associated with fractures of the medial malleolus or disruption of the deltoid ligament. Tenderness of the proximal fibula is the most important clinical clue to this diagnosis.

Ankle films may show a widened medial clear space and decreased tibiofibular overlap, but they will miss the proximal fibular fracture (for which leg or knee films are required).

Talar Dome Fractures

Fractures of the lateral process of the talus result from forces applied to an inverted, dorsiflexed foot;³³⁻³⁵ thus, it is not surprising that these injuries are common in snowboarders.^{8,33,36} Unless the emergency physician suspects this injury, the diagnosis can be elusive. Typically, these patients present after forced inversion with lateral ankle pain (like those with lateral ankle sprains do), and they may not meet strict criteria for undergoing ankle radiography. Even when films are ordered, abnormalities may be subtle. Some investigators have suggested positioning the foot in varying degrees of internal rotation and plantar flexion to accentuate the fracture.^{37,38} CT is considered by many to be the study of choice in patients in whom this injury is suspected.³⁹⁻⁴¹

Tibial Plafond (Pilon) Fractures

These dramatic, intra-articular fractures of the distal tibial diaphysis typically result from axial loading forces, such as a fall or jump from a significant height or a head-on motor vehicle collision.^{14,32,42} Forced dorsiflexion at the ankle joint drives the talus into the tibia and usually creates a comminuted fracture of the plafond, with loss of mortise integrity.

Pilon fractures may be open and are often accompanied by fractures of the medial malleolus and fibular shaft. They frequently occur in association with other axial loading injuries such as calcaneal, tibial plateau, hip, pelvic, and lumbosacral fractures. Patients with pilon fractures should be questioned specifically about pain or tenderness in any of these areas. Order additional plain films based on clinical suspicion and tenderness of the involved structures.

A lateral ankle x-ray may reveal joint impaction,⁴² although the radiographic appearance of this fracture is usually not subtle. The orthopedist may use

CT to better evaluate the injury and develop an operative plan,⁴²⁻⁴⁴ but CT has limited utility in the acute setting.⁴⁵

Advanced Salter-Harris Fractures (III-IV)

Tillaux Fracture

This biplanar avulsion fracture of the distal tibia typically occurs among adolescents when forceful ankle eversion disrupts the unfused, immature, lateral portion of the distal tibial epiphyseal plate, producing a fracture in the sagittal plane through the lateral third of the tibial plafond (epiphysis).^{32,46} The avulsed epiphyseal fragment is laterally displaced to varying degrees by intact tibiofibular ligaments. The Tillaux fracture is a variant of the Salter-Harris type III physeal injury (see also page 22), and minimally displaced fragments may be difficult to visualize on x-ray. If the emergency physician suspects the presence of this fracture, CT can provide specific details regarding the size, location, and degree of displacement of the avulsed fragment.^{32,47}

Triplane Fracture

The triplane fracture encompasses three distinct fractures of the distal tibia that result from forceful ankle eversion in adolescents, namely: 1) a metaphyseal fracture oriented in the coronal plane; 2) an epiphyseal fracture oriented in the sagittal plane; and 3) an epiphyseal plate disruption oriented in the transverse plane. It is essentially a Tillaux fracture with a posterior malleolar (metaphyseal) component. As in the case of the biplanar Tillaux fracture, this characteristic triplanar fracture pattern results from forces applied to a partially fused growth plate. Triplane fractures are a variant of the Salter-Harris type IV physeal injury (see also page 22).

Proximal Fifth Metatarsal Shaft Fracture (Jones Fracture)

Robert Jones originally described this fracture in 1902 after he sustained the injury while dancing.⁴⁸ (An unconfirmed report suggests he was doing the “Hokey-Pokey” at the time.) It results from a direct blow or repetitive stress to the lateral aspect of the foot. This injury typically involves a transverse fracture of the proximal metatarsal shaft *and must be distinguished from the less significant avulsion fracture of the tuberosity (pseudo-Jones fracture)*. The pseudo-Jones fracture occurs at, or proximal to, the distal aspect of the cuboid, whereas the Jones fracture is usually even with, or slightly distal to, the distal cuboid.

Fractures of the proximal metatarsal shaft commonly present with pain at the lateral aspect of the ankle or foot and may be difficult to diagnose if the emergency physician fails to palpate the fifth metatarsal carefully in all patients who complain of ankle injury. If the base of the fifth metatarsal is tender, order foot films in addition to (or instead of, depending on

the clinical examination) ankle films.

Prehospital Care

Prehospital care providers should treat ankle-injured patients as they would any trauma victim. Given an appropriate mechanism, medics must attend to the patient’s airway, breathing, circulation, and neurologic status, including protection of the cervical spine. They should check pulses in the foot and note the color and temperature of the extremities. Bleeding should be managed with direct pressure and elevation of the extremity.

As a general principle, the injured extremity should be elevated and cooled with an ice pack to minimize swelling. Medics should splint all suspected fractures and dislocations and place sterile gauze over open fractures.

“A lame crab walks straight.”—Afghan proverb

Emergency Department Evaluation

Triage/Stabilization

Open wounds associated with gross ankle deformities, tenting of the overlying skin, or a cool, pulseless, or dusky foot should alert the ED staff to a potential limb-threatening injury. *If vascular compromise occurs with a dislocation, emergently reduce the ankle.* Unless they can be obtained *immediately*, diagnostic imaging and orthopedic consultation must not delay the reduction.

Reduce the foot by providing adequate analgesia and positioning the patient supine with the knee flexed (to relax the Achilles tendon). An assistant then provides counter-traction to the leg as the emergency physician applies downward traction to the foot and heel while rotating the talus in a direction opposite to that of the deforming forces that caused the injury.⁴⁹ After reduction, reassess the dorsalis pedis and posterior tibial pulses, along with capillary refill to determine the adequacy of revascularization. Open wounds should be covered with moist sterile gauze to limit contamination, and the ankle should be placed in a posterior splint to maintain the reduction. The injured ankle should be elevated; cooling may minimize swelling and prevent further soft-tissue damage.¹⁷ Determine the need for tetanus immunization and antibiotics.

After the reduction, complete the history and physical examination. Assess (and reassess) the adequacy of analgesia. Obtain x-rays and orthopedic consultation as indicated.

History

One of the primary goals is to determine what forces were involved in the injury (inversion, eversion, external rotation, forced dorsiflexion, etc.). This information helps predict specific injury patterns and adds focus to the physical examination.

Question patients specifically about the setting in which the injury occurred,^{8,33,36,50} the magnitude and direction of the forces involved,⁵¹ and the foot position or ankle motion at the moment of loading.^{31,52} Determine whether the patient has specific areas of pain⁵³ and whether he or she was able to walk immediately after the injury.⁵⁴ Also inquire about prior injuries to the same limb⁵⁵ or any coexisting medical conditions.^{56,57} Interestingly, the agonizing snapping or popping sounds heard at the time of injury are more likely to represent soft-tissue pathology rather than fracture.⁵⁹

If the patient is unconscious, intoxicated, paralyzed, or multiply injured, the emergency physician must focus on the physical examination (and imaging studies to rule out the presence of significant pathology).⁵⁸

Physical Examination

If possible, observe patients as they enter the treatment room. Typically, patients who are able to ambulate either at the scene or in the ED are unlikely to have an unstable injury or significant fracture.^{3,53,58}

There is more to the ankle examination than the ankle itself. Palpate the foot, especially the navicular bone medially and the base of the fifth metatarsal laterally, in all patients with ankle injuries. The navicular and base of the fifth metatarsal are the foot bones most likely to be injured in patients who stumble or twist their "ankle." Similarly, be sure to examine the leg and knee (and especially the entire fibula) in patients with ankle complaints.

Inspect the ankle and foot for gross appearance, color, temperature, position, and open wounds. Popliteal, posterior tibial, and dorsalis pedis pulses should be individually assessed. Note any swelling and ecchymosis, but avoid overreliance on these physical findings. Swelling and ecchymosis are difficult to quantify, depend on the time between injury and physical examination, and fail to accurately predict specific injuries.⁵⁵ Palpate the entire leg and foot, starting proximally at the knee and moving distally along the entire shaft of the tibia and fibula to the tip of each malleolus, *paying particular attention to the tip and posterior aspect of the distal 6 cm of each bone.* There are relatively few ligamentous insertions in this area, and tenderness suggests fracture. In addition to bony injury, be sure to consider the possibility of damage to the ligaments and tendons. Patients who present with ankle pain may have suffered injury to the peroneus longus, peroneus brevis, tibialis posterior, or Achilles tendons. Tendon injury is best detected by examining forced resistance to a tendon motion or by a provocative maneuver such as the Thompson squeeze test (as described later in the text).

Ligamentous injury is best determined by stressing the joint. *After* adequate analgesia, the clinician should consider the following provocative maneuvers based

on the mechanism of injury or initial examination. They are usually not indicated in the patient with an obvious fracture or dislocation.

Although provocative maneuvers can identify unstable injury patterns, some authors suggest that the anterior drawer test and talar tilt test (as described later) cannot effectively differentiate between isolated ATFL tears and combined ATFL/CFL tears.⁶⁰ This poor clinical correlation between stress tests and the degree of ligamentous disruption makes the utility of such tests somewhat controversial. One study prospectively enrolled 160 consecutive patients with inversion trauma of the ankle. The diagnostic protocol included physical examination within two days and at five days after trauma, arthrography, stress radiography, and ultrasonography. Delayed physical examination at five days after the injury led to the highest overall sensitivity (96%) and specificity (84%) for the detection of a ligament rupture. Additional diagnostic procedures (at a considerable cost) yielded little additional information.⁶¹

Anterior Drawer Test

This test evaluates the integrity of the ATFL and CFL and is most often used in the patient with an inversion injury. With the patient's knee in flexion and foot in plantar flexion, the examiner attempts to draw the heel of the injured side anteriorly while stabilizing the leg posteriorly with the non-dominant hand.⁶² Approximately 20 pounds of anterior force is adequate to elicit an abnormal result.⁶³ Injury to the ATFL or CFL is indicated by 2 mm or more of anterior subluxation of the foot, visible dimpling of the anterior skin over the ankle (suction sign), or a soft poorly defined endpoint as compared with the uninjured side.^{2,64-67} If significant edema or guarding is present, the Gungor test may be used to evaluate these same ligaments. With the patient prone on the stretcher, attempt to displace the talus anteriorly from its cup by applying a downward force to the heel. A positive test is indicated by visualizing improved definition of the Achilles tendon as the overlying skin stretches excessively in the presence of a lax joint.⁴

Squeeze Test

This test evaluates the integrity of the distal tibiofibular syndesmosis. It is especially useful in those who have sustained a mechanism of forced hyper-dorsiflexion or external rotation. It is performed with the patient sitting at the edge of the stretcher with the knee flexed at 90°. A compressive force is applied simultaneously to the *proximal shafts* of the tibia and fibula in an attempt to cause diastasis of these bones distally at the ankle. A positive test is indicated by increased pain at the *ankle* during the maneuver.^{2,25} The examiner must consider the presence of a Maisonneuve fracture of the fibula if a patient reports pain proximally over the fibular head during this maneuver.

“Can this be a stalwart man’s work, who has a marrow in his back and a tendon Achilles in his heel?”—Henry David Thoreau, U.S. philosopher, author, naturalist⁶⁸

Evaluation Of Achilles Tendon Rupture

Tests of the integrity of the Achilles tendon are indicated when the patient complains of difficulty walking, especially after a mechanism in which they landed on the balls of their dorsiflexed feet after jumping. *Patients who have ruptured their Achilles tendon can still plantar flex their foot using their toe flexors.* One means of detecting an Achilles tendon rupture involves placing the patient’s foot in dorsiflexion and palpating the posterior ankle for a defect in the tendon. The injury is often obvious when comparing the injured and uninjured legs.

The integrity of the Achilles tendon can also be evaluated by the Thompson (calf squeeze) test or Matles test.⁶⁹

The Thompson test is performed with the patient lying prone and the knee flexed at 90°. A compressive force applied to the midcalf (gastrocnemius and soleus) muscles should result in plantar flexion of the foot if the tendon is intact.

During the Matles test, active or passive flexion of both knees to 90° will result in similar degrees of plantar flexion when comparing the ankle and foot position of the injured and uninjured sides in patients without tendon rupture. The Achilles tendon is ruptured if the foot falls into neutral position or dorsiflexes during this test, as compared with the uninjured ankle.

Another clever test for an Achilles tendon rupture involves laying the patient prone with the knee flexed

(just as in the case of the Thompson squeeze test). Place a blood pressure cuff on the injured leg and inflate it to 50 mmHg or so. Subsequent dorsiflexion of the foot should significantly raise the pressure on the sphygmomanometer dial if the Achilles tendon is intact. Dorsiflexion will *not* significantly affect the cuff pressure when the tendon is ruptured.⁷⁰

Ankle Radiography

Ottawa Ankle Rules

Plain films of the ankle are one of the most frequently ordered radiographic series in ED patients with musculoskeletal trauma, second only to cervical spine films.⁷¹ Each year in North America, we spend approximately \$500 million on ankle radiography,³ yet fewer than 15% of those films show a clinically significant fracture.^{1,72} The question of when to order ankle x-rays has stimulated more than four decades of clinical debate.^{3,73-76}

In the early 1990s, a Canadian group developed clinical decision rules (CDRs) for ankle radiography. These rules attempt to reduce costs by eliminating unnecessary ankle x-rays.^{3,53,58}

The Ottawa Ankle Rules (OAR) are a prospectively developed,⁵³ refined,³ and validated⁵⁸ CDR for ankle radiography. Several well-conducted trials show that they significantly reduce the overall number of ankle x-rays ordered,^{3,52,58,82,87-91} ED length of stay,^{58,88} and costs associated with the management of ankle injuries.^{79,88,91} These savings come without the added expenses of missing clinically significant fractures or negatively impacting patient satisfaction.^{58,88}

The Ottawa Ankle Rules are a clearly defined set of historical and physical exam criteria that, if

Cost-Effective Strategies For Patients With Ankle Injuries

1. Use the Ottawa Ankle Rules to determine who needs an x-ray.

Studies show that using the Ottawa Ankle Rules can decrease both the time patients spend in the ED and cost of unnecessary radiography. In one financial analysis, researchers calculated the costs of radiography, waiting time, lost productivity, and medicolegal monies associated with ankle injuries. In the United States, estimated savings associated with using the Ottawa Ankle Rules varied between \$614,226 and \$3,145,910 per 100,000 patients, depending on the charge rate for radiography.⁷⁹ The Ottawa Ankle Rules save time as well. In one study, non-fracture patients discharged without radiography spent an average of 36 minutes less time in the ED than those who underwent radiography (80 minutes vs 116 minutes; $P < 0.0001$).⁵⁸

2. Allow triage nurses to use the Ottawa Ankle Rules in order to obtain x-rays *before* the patient sees a physician.

Time is money. At least one study shows that the use of the Ottawa Ankle Rules by triage nurses can significantly reduce the ED length of stay for patients with ankle injuries.¹³² Other studies confirm that nurses can apply the Ottawa Ankle Rules safely without missing acute fractures.¹³³

3. Consider the use of an Ace wrap or taping instead of prefabricated splints in patients with simple ankle sprains.

Studies show that early return to activities as tolerated improves outcome better than prolonged immobilization. The functional outcome using an Ace wrap appears equivalent to that of the more expensive “high-tech” splints. ▲

met, suggest a reasonable likelihood of clinically significant ankle fracture. Studies show that in the absence of the Ottawa criteria, ankle radiography shows either no fracture or a relatively minor one (such as an avulsed fragment or chip fracture less than 3 mm). These clinically insignificant fractures are treated with conservative therapy, similar to a low-grade ankle sprain.

The Ottawa Ankle Rules advise the clinician to order an ankle film if a patient complaining of post-traumatic ankle pain has either of the following:⁵⁸

1. The patient is unable to ambulate at least four steps (two on the injured ankle) *both* at the time of injury and in the ED.
2. There is point tenderness upon palpation of the tip or distal 6 cm of the posterior aspect of either malleolus.

According to the Ottawa Ankle Rules, a foot x-ray is indicated if patient complains of midfoot pain and has either of the following (see also Figure 5):

1. The patient is unable to ambulate four steps *both* at

the scene and in the ED.

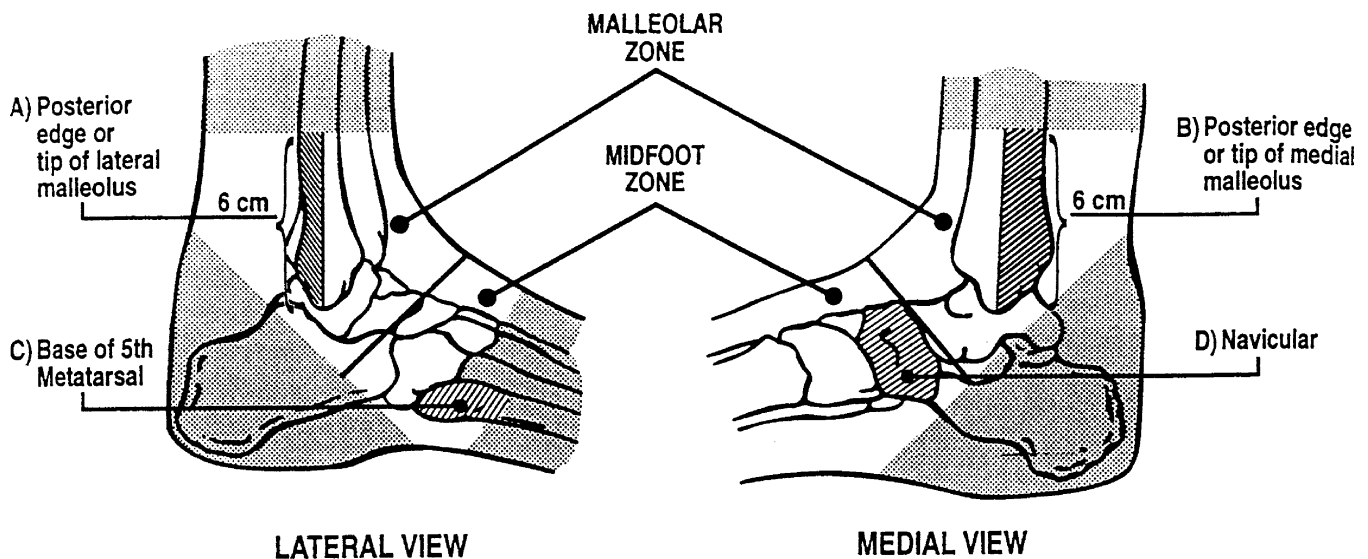
2. There is point tenderness over *either* the proximal fifth metatarsal or the navicular bone.

While the vast majority of the literature demonstrates very high sensitivity of the Ottawa Ankle Rules (nearly 100%), there have been reports of spotty performance in some locales. In one Asian study, the sensitivity was only 90%,⁹² and in one New Zealand study, there were 75 fractures in 350 patients, five of which would have been missed by the clinical decision rule (sensitivity, 93%; false-negative rate, 14%).⁷⁷

Physician And Patient Expectations

In a survey of physicians in five countries, more than 70% of all responding Canadian and United Kingdom physicians frequently used the rules, compared with fewer than one-third of U.S., French, and Spanish physicians. Of all physicians, those from the United States held the least positive attitudes toward the decision rules.⁸⁶ However, once physicians learn these rules, they are likely to continue to use them. In one study, researchers taught physicians the OAR and

Figure 5. The Ottawa Ankle Rules for ankle and midfoot injuries.



- a) An ankle x-ray series is only required if:
 - There is any pain in malleolar zone and any of these findings:
 - i) bone tenderness at A **or**
 - ii) bone tenderness at B **or**
 - iii) inability to bear weight both immediately and in the ED
- b) A foot x-ray series is only required if:
 - There is any pain in midfoot zone and any of these findings:
 - i) bone tenderness at C **or**
 - ii) bone tenderness at D **or**
 - iii) inability to bear weight both immediately and in the ED

Reproduced with permission from: Michael JA, Steill IG. Ankle injuries. In: Tintinalli JE, Kelen GD, Stapczynski JS, eds. *Emergency Medicine: A Comprehensive Study Guide*. New York: McGraw-Hill; 2000:1828. Figure 268-2.

provided them with feedback regarding their compliance. Compliance with the OAR was sustained during the following year, even when physicians did not know they were being observed.⁹³ Use of a laminated pocket card or wall poster may be helpful during the educational phase.

Some emergency physicians are reluctant to use the OAR for fear that the patient who comes to the ED with an ankle injury expects an x-ray. (Chief complaint at triage: "Need x-ray of ankle.") One prospective study showed that patients' satisfaction with care does not depend on whether they get x-rays of the foot or ankle.⁹⁴ In this same study, 76% of physicians supported the use of the OAR; however, 78% reported that patient expectations influenced their application of these rules. When a physician decides not to order an x-ray, it may be helpful to explain this decision to the patient. ("We only take x-rays of broken ankles, not sprained ankles. These tests I just did show that you have an ankle sprain, not a break.")

Radiographs

The standard ankle radiographic series includes three views—the AP, lateral, and mortise^{32,95-97}—although some

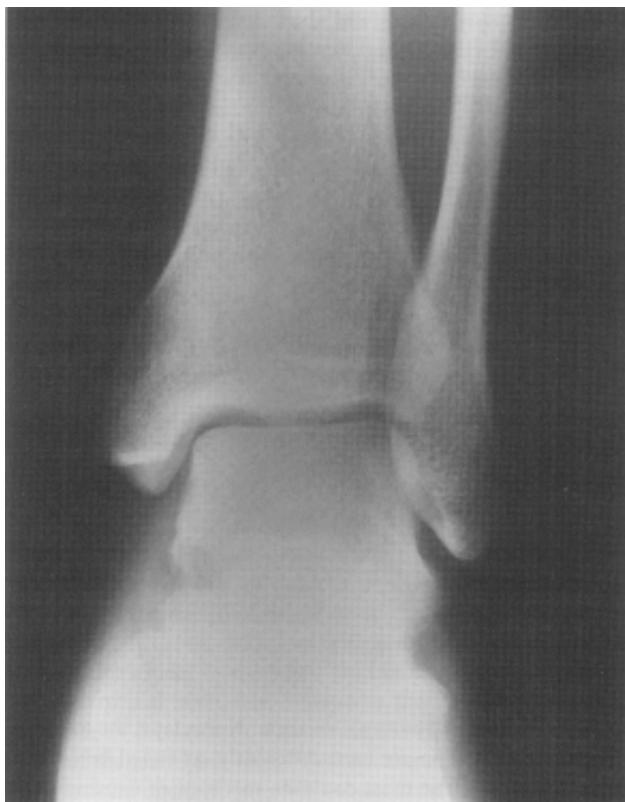authors consider a fourth, the externally rotated oblique view, to provide additional diagnostic accuracy.⁴⁶

The AP view demonstrates the medial and lateral malleoli and an oblique view of the talar dome. However, it fails to reveal the entire talocrural joint space due to the superimposition of the fibula on the lateral aspects of the tibia and talus. (See **Figure 6.**) The lateral view visualizes the anterior and posterior elements of the distal tibia, including the posterior malleolus, as well as the base of the fifth metatarsal. It is also useful for defining the extent and configuration of lateral malleolar fractures. (See **Figure 7.**)

The mortise view is filmed like an AP, except the leg is internally rotated 15°-20°. This positioning provides a true AP view of the talus, revealing the entire joint space, both malleoli, and the breadth of the talar dome. On the mortise view, the width of the joint space should be uniform, and tibia and fibula should overlap. (See **Figure 8** on page 11.) *Any asymmetry of the joint space or decrease in the amount of tibiofibular overlap suggests fracture, injury to the syndesmosis or deltoid ligament, or any combination thereof.*

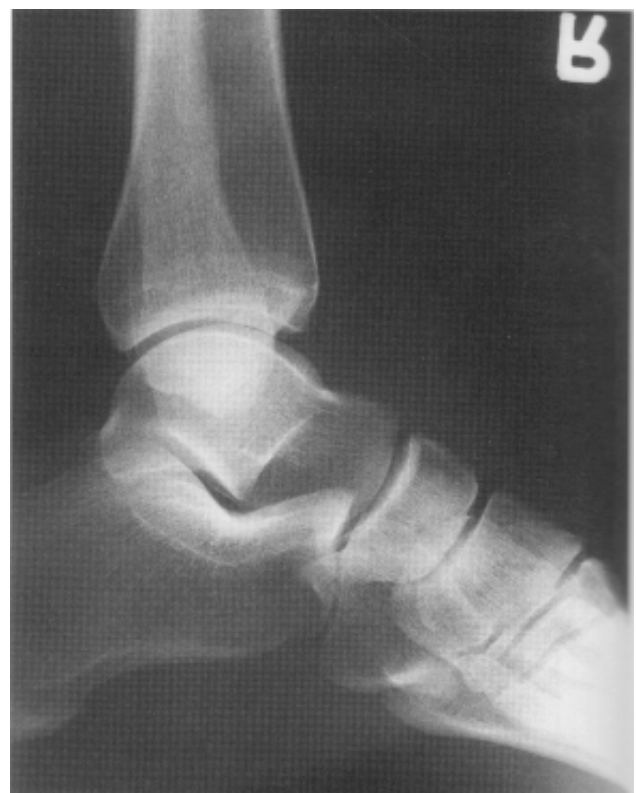Stress radiographs rarely provide useful information in the ED. Because of the lack of consistent criteria for interpreting stress radiography of the foot and

Figure 6. Anteroposterior x-ray of the ankle.



Reproduced with permission from: Williamson B, Schwartz DT. The ankle and leg. In: Schwartz DT, Reisdorff EJ, eds. *Emergency Radiology*. New York: McGraw-Hill; 2000:160. Figure 9-5a.

Figure 7. Lateral x-ray of the ankle.



Reproduced with permission from: Williamson B, Schwartz DT. The ankle and leg. In: Schwartz DT, Reisdorff EJ, eds. *Emergency Radiology*. New York: McGraw-Hill; 2000:160. Figure 9-5c.

ankle, their overall utility has been questioned.⁹⁸

Interpretation Of Ankle Radiographs

When reviewing ankle radiographs, screen the films to ensure that they are adequate and were taken at the correct angle. On the AP view, the lateral distal tibia and the medial fibula should overlap. On the AP view, at least 6 mm of tibiofibular overlap is normal; a lesser amount suggests injury to the syndesmosis.^{32,99}

On the lateral view, the malleoli should be superimposed on each other, and the body of the calcaneus should be visible. The base of the fifth metatarsal is present on both the lateral and mortise views.³²

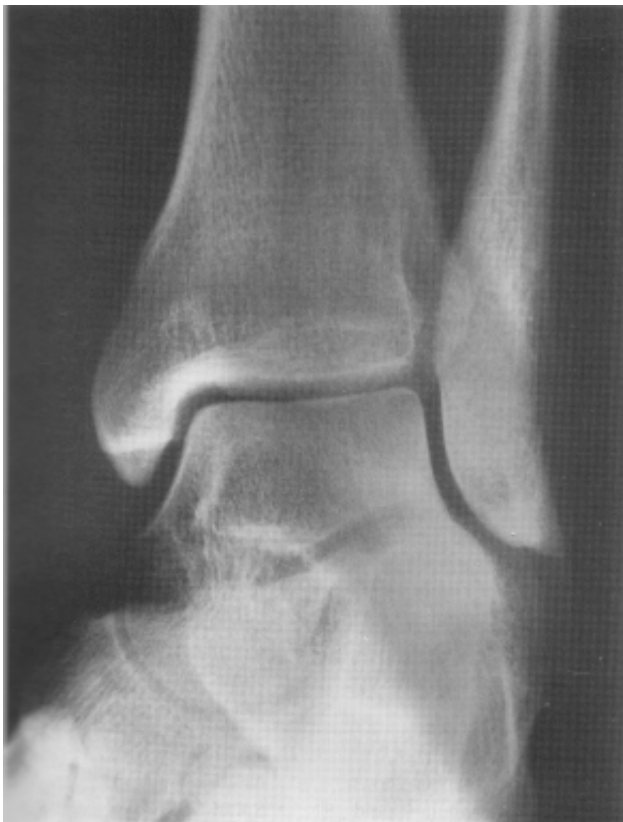On the mortise view, the entire joint space and talar dome should be revealed without overlap. *On this view, make sure the joint space appears symmetrical.* The width of the medial clear space (area bounded by the

lateral border of the medial malleolus and medial border of the talus) should not exceed 2-3 mm,¹⁰⁰ and the amount of tibiofibular overlap should be no less than 1-2 mm.^{32,99} Widening of the medial clear space or a lesser degree of tibiofibular overlap suggests injury to the medial ligament, syndesmosis, or both.²³

Look at the proximal portion of the fibula and note the location of any fibular fractures with respect to the mortise. Fractures of the base of the fifth metatarsal, navicular, talus, and calcaneus are most easily visualized on the lateral view (or on films of the foot).

Two small studies assessed the predictive value of an ankle effusion visualized on plain radiographs in the absence of fracture. They concluded that an effusion of 15 mm or greater in combined anterior and posterior capsular distention is 86% specific for the presence of an occult fracture, with an 83% positive predictive value.^{101,102}

Figure 8. Mortise x-ray of the ankle.



Reproduced with permission from: Williamson B, Schwartz DT. The ankle and leg. In: Schwartz DT, Reisdorff EJ, eds. *Emergency Radiology*. New York: McGraw-Hill; 2000:161. Figure 9-5e.

Fracture Classification

The two most commonly used fracture classification schemes are based on either mechanism of injury or anatomic location of the fracture. The Lauge-Hansen (LH) classification utilizes mechanism of injury and classifies ankle injuries based on the position of the foot with respect to the ankle (supination or pronation) and the motion of the talus within the mortise (adduction, abduction, or external rotation) at the moment of injury.³¹ (See Table 1.) (While a good history is laudable and helpful, there is not an emergency physician alive who has not heard the classic lament, "I don't know how it happened, I just twisted it!")

In contrast, the Weber or Danis-Weber (DW) classification scheme groups injuries according to anatomic location of the fibular fracture.¹⁰³ (See Figure 9 on page 12.) This system is useful, since the level of the fibular fracture determines the integrity of the syndesmosis and thus the need for operative repair. Fortunately, the two classification schemes overlap. (See Table 1.)

Weber type A injuries include fractures of the lateral malleolus *below* (distal to) the mortise and are managed non-operatively. (See Figure 9a on page 12.) Weber type B injuries feature fibular fractures *at* the level of the mortise and are stable only if the fibular fracture occurs in isolation; medial joint involvement creates an unstable situation that requires operative correction in the majority of cases. (See Figure 9b.) Weber type C injuries include fibular fractures *above*

Table 1. Classifications Of Ankle Injuries.

Lauge-Hansen Fracture Classification

supination-adduction (inversion)
pronation-abduction (eversion)
supination-external rotation
pronation-external rotation
dorsiflexion (axial loading)

Danis-Weber Classification

Type A (below mortise)
Type B (at mortise)
Type B
Type C (above mortise)
Type C

(proximal to) the mortise. Because these injuries disrupt the syndesmosis distal to the fracture, they require open reduction and internal fixation (ORIF) to repair the damage. (See Figure 9c.)

“Disease is very old, and nothing about it has changed. It is we who change as we learn to recognize what was formerly imperceptible.”—Jean Martin Charcot

Patterns Of Injury

Inversion Injuries

Lateral Ankle Sprains

Patients who report a mechanism of ankle inversion or supination-adduction (SA) are likely to have a lateral collateral ligament injury. This usually involves a complete or partial tear of the ATFL and/or the CFL. Physical examination of these patients reveals varying degrees of edema, ecchymosis, tenderness, and weight-bearing ability. Partial ATFL tears, which result in little or no instability of the joint, are termed Grade I sprains. Typically, these patients are able to bear weight on the injured extremity and ambulate without limping. Grade II sprains involve partial tears to both the ATFL and CFL. These patients have difficulty bearing weight and ambulate with an obvious limp. Grade III sprains are complete tears of both the ATFL and CFL. Patients with this injury are usually unable to bear weight and have greater than 2 mm of anterior subluxation of the talus as compared with the uninjured side, or demonstrate a suction sign (visible dimpling of the anterior skin of the ankle) during the anterior drawer or Gungor test.⁴ The talar tilt test suggests a lateral collateral ligament injury when there is greater than a 5%-10% difference in talar translation between the injured and uninjured sides upon application of varus stress.^{2,65,104}

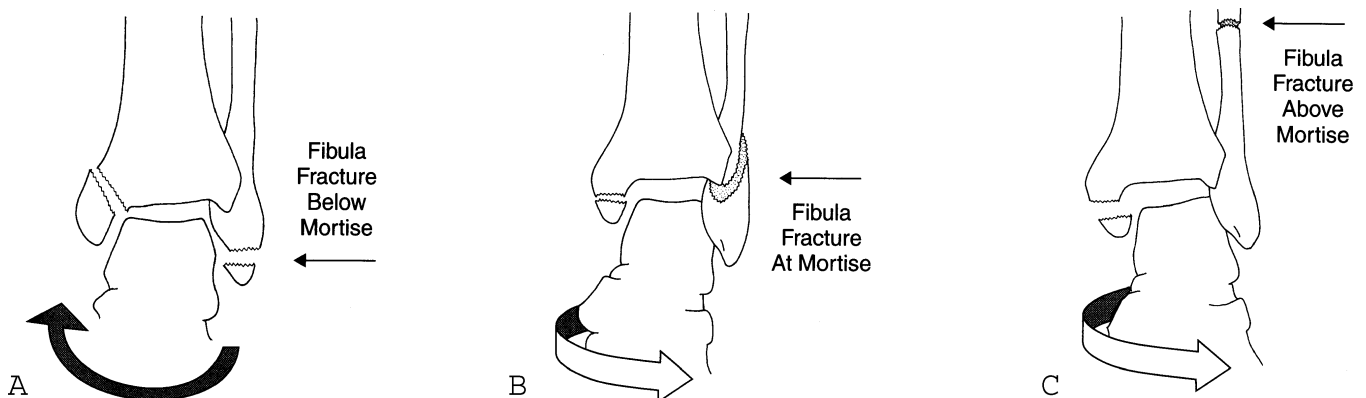
Patients with grade I, II, or III sprains heal without operative management,^{19,22,105} particularly if they adhere to a rest, ice, compression, and elevation (RICE) regimen.^{85,106-108} For lateral sprains with little or no instability, a soft compression dressing may be applied for added support and protection. Patients with grade III sprains should be splinted, placed on crutches, and referred to an orthopedist for follow-up care.^{100,109}

Although lateral collateral ligamentous injuries often occur in isolation, forced inversion also contributes to subtalar and medial ligament sprains and/or fractures of the tibia, fibula, calcaneus, or talus. Subtalar sprains involve injury to structures that stabilize the talocalcaneal joint and are a frequent cause of chronic ankle instability. In the acute setting, these injuries present similarly to lateral ankle sprains, making it difficult to distinguish between the two entities. Some orthopedists use stress radiographs (Brodén’s view, anterior drawer lateral projection) in patients with significant subtalar instability to diagnose subtalar sprains,¹⁰⁰ although the ED management is the same for both types of injury.

Fractures

Supination-adduction forces stress the lateral ligaments, either tearing them completely or avulsing a fragment of bone from the distal tip of the lateral malleolus (SA grade 1 injury). (See Figure 10 on page 13.) With continued forces, the injury extends to the medial side, causing an oblique fracture of the medial malleolus (SA grade 2 injury). SA1 injuries involve either an isolated tear of the lateral collateral ligaments or a transverse fracture of the lateral malleolus *below* the mortise, whereas SA2 injuries demonstrate an additional oblique fracture of the medial malleolus. Ankle fractures in the LH SA group are essentially the same as those classified as DW type A. (See Table 1 on

Figure 9. The Danis-Weber classification system of ankle fractures. This system is based on the level of the fibula fracture. A) Fractures below the mortise (type A) are typically stable; B) fractures at the mortise (type B) may be stable or unstable depending upon the integrity of the tibiofibular syndesmosis; C) fractures above the mortise (type C) are unstable and require surgical correction.



Reproduced with permission from: Williamson B, Schwartz DT. The ankle and leg. In: Schwartz DT, Reisdorff EJ, eds. *Emergency Radiology*. New York: McGraw-Hill; 2000:167. Figure 9-10.

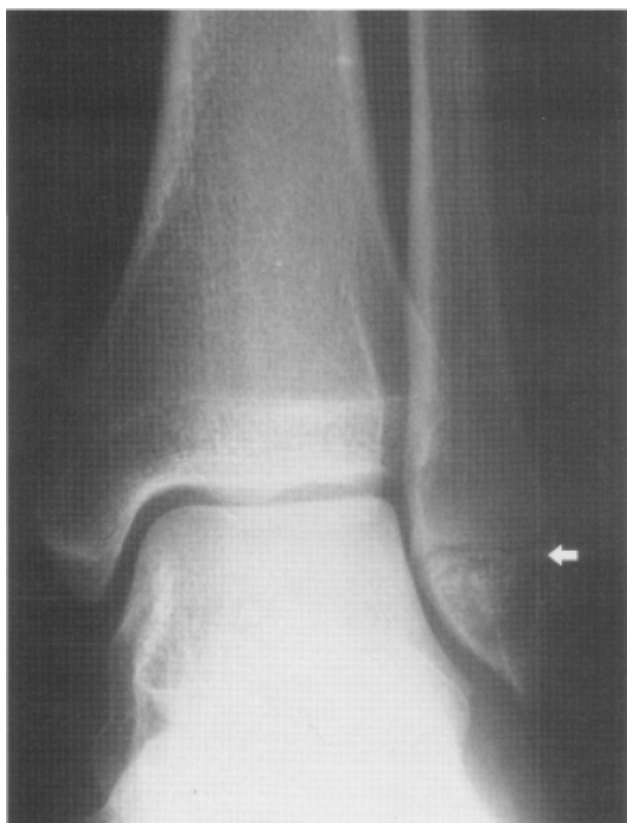page 11.) Type A injuries are fibular avulsion fractures of the lateral malleolus *below* the mortise (SA1), accompanied by oblique fractures of the medial malleolus (SA2).

Like isolated lateral ankle sprains, SA or type A injuries are usually managed non-operatively utilizing a RICE (rest, ice, compression, elevation) protocol, unless a medial malleolar fracture is present or the joint is grossly unstable.¹¹⁰ Forced inversion of the ankle also produces avulsion or chip fractures of the anterior process of the calcaneus and lateral process of the talus.

Proximal Fifth Metatarsal Shaft Fracture (Jones Fracture)

Because of the poor blood supply to the proximal fifth metatarsal, Jones fractures that are missed or treated inadequately may progress to nonunion and chronic disability.⁴ Patients with a Jones fracture should be placed in a short leg cast for 6-8 weeks, receive crutches, and instructed not to bear weight.² They

Figure 10. Inversion injury. There is a transverse avulsion fracture of the lateral malleolus below the mortise caused by supination-adduction forces (arrow). The lateral ligaments remain intact. This injury is classified as Lauge-Hansen SA grade 1 or Danis-Weber type A.



Reproduced with permission from: Williamson B, Schwartz DT. The ankle and leg. In: Schwartz DT, Reisdorff EJ, eds. *Emergency Radiology*. New York: McGraw-Hill; 2000:169. Figure 9-12.

should follow up with an orthopedist as an outpatient.

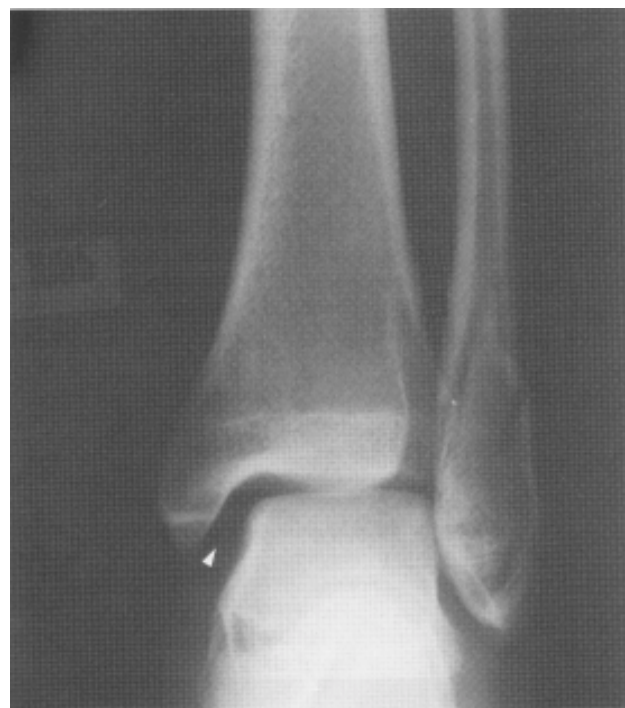Pseudo-Jones fractures (avulsion fractures of the distal fifth) heal quickly and without sequelae. Patients may be given a hard cast shoe for comfort.⁴⁵

Eversion Injuries Medial Ankle Sprains

Injury to the medial collateral ligaments typically results from forced eversion, with the foot pronated and the talus abducted at the moment of loading—in other words, pronation-abduction (PA) forces. Deltoid ligament tears are less common than lateral ligament injuries, constituting fewer than 5% of all ankle sprains.¹¹¹ Patients typically present with pain, swelling, and tenderness at the medial aspect of the ankle, with varying degrees of joint instability and weight-bearing difficulty. The grading of medial ankle sprains is similar to that of lateral injuries. Talar tilt testing is often positive in patients with grade II or III type injuries, as evidenced by increasing degrees of talar translation upon the application of a valgus stress. On plain radiographs, more than 2-3 mm of widening of

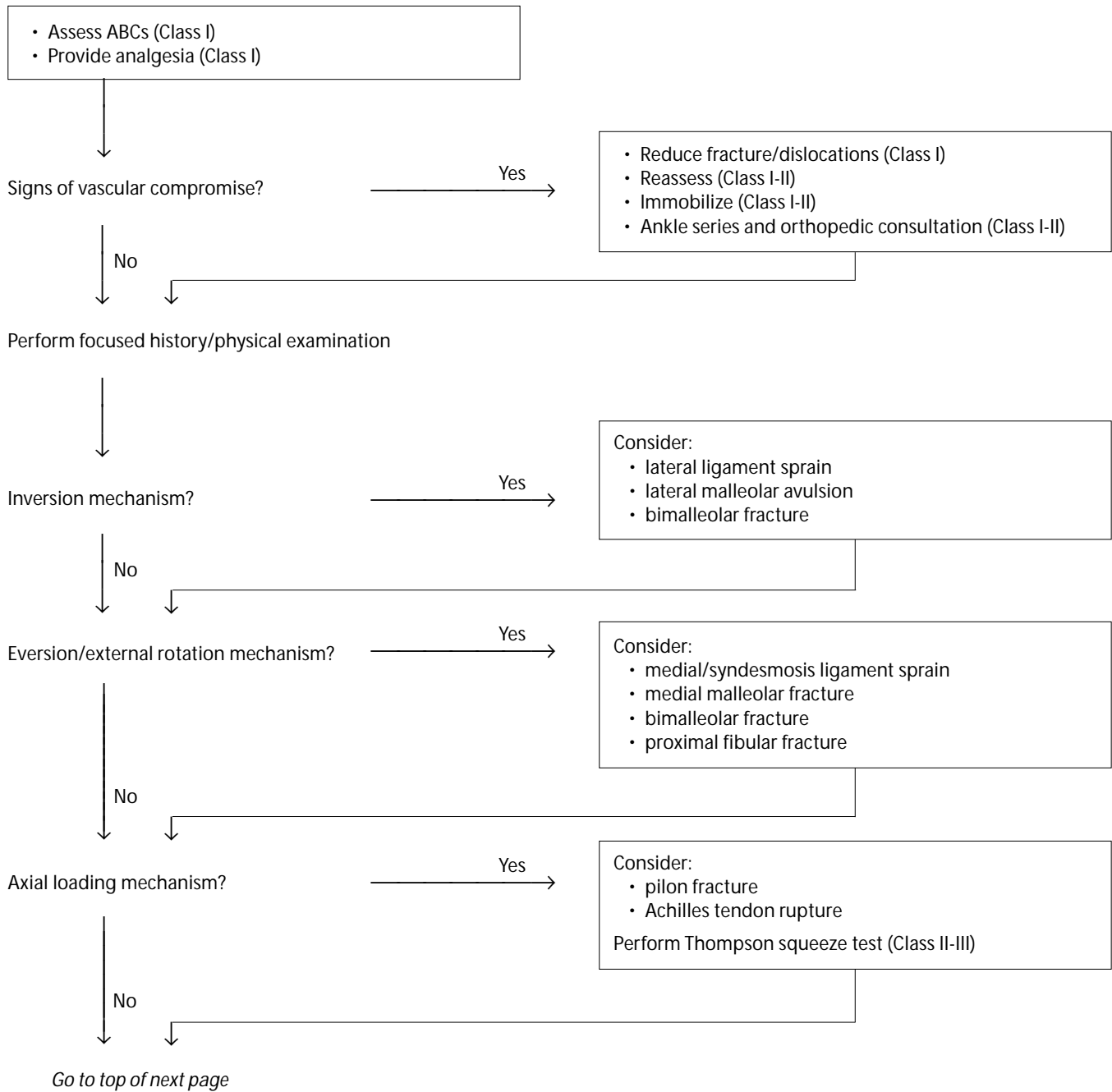
Continued on page 18

Figure 11. The medial clear space is widened, suggesting deltoid and/or syndesmotic ligament disruption (arrowhead). There is an isolated spiral fracture of the fibula occurring at the level of the mortise caused by supination-external rotation forces. This injury is classified as Lauge-Hansen SE grade 2 or Danis-Weber type B.



Reproduced with permission from: Williamson B, Schwartz DT. The ankle and leg. In: Schwartz DT, Reisdorff EJ, eds. *Emergency Radiology*. New York: McGraw-Hill; 2000:170. Figure 9-13a.

Clinical Pathway: Evaluation Of Ankle Injuries

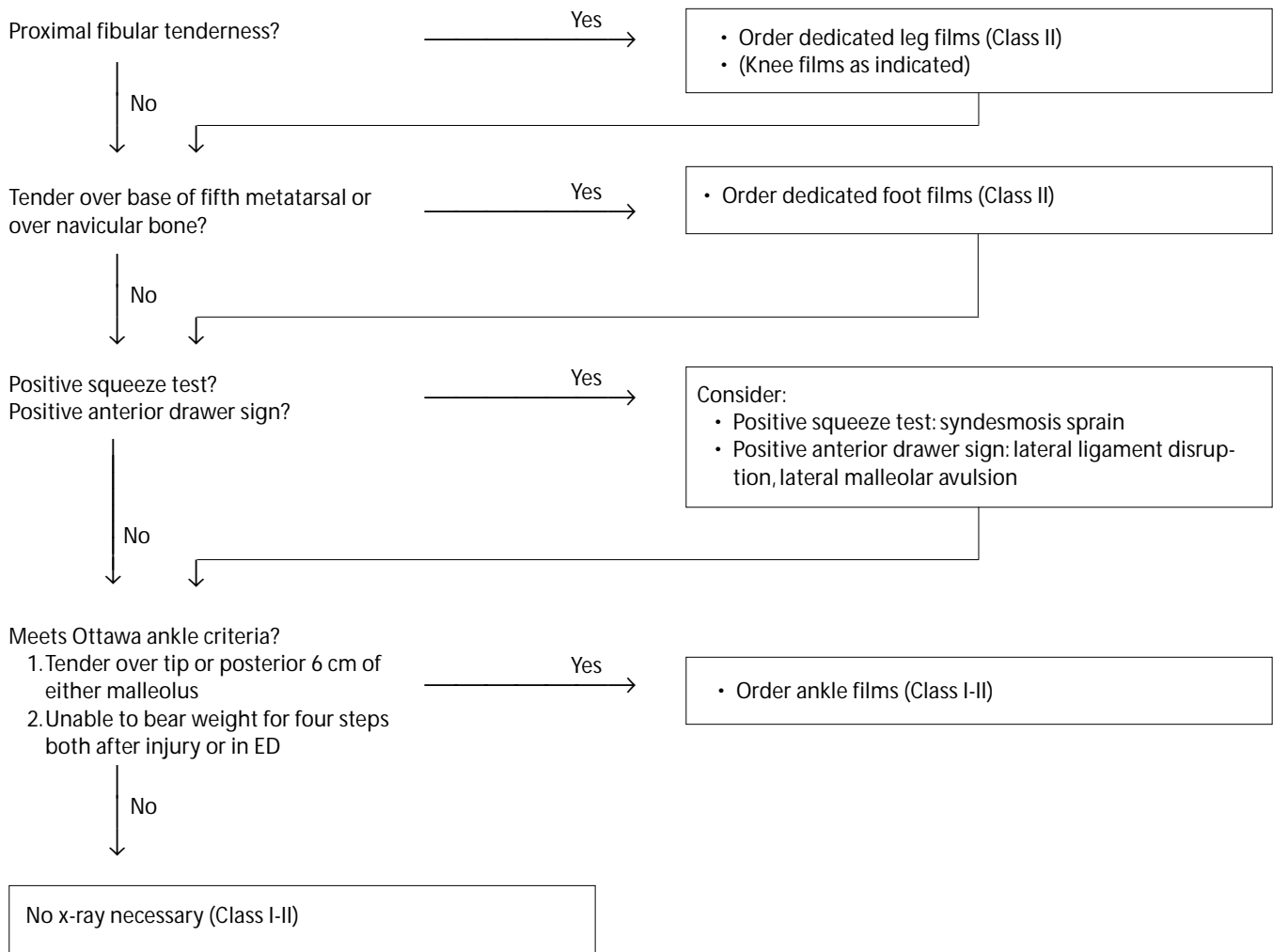


The **evidence for recommendations** is graded using the following scale. For complete definitions, see back page. **Class I:** Definitely recommended. Definitive, excellent evidence provides support. **Class II:** Acceptable and useful. Good evidence provides support. **Class III:** May be acceptable, possibly useful. Fair-to-good evidence provides support. **Indeterminate:** Continuing area of research.

This clinical pathway is intended to supplement, rather than substitute for, professional judgment and may be changed depending upon a patient's individual needs. Failure to comply with this pathway does not represent a breach of the standard of care.

Copyright © 2002 EB Practice, LLC. EB Practice, LLC (1-800-249-5770) grants each subscriber limited copying privileges for educational distribution within your facility or program. Commercial distribution to promote any product or service is strictly prohibited.

Clinical Pathway: Evaluation Of Ankle Injuries (continued)

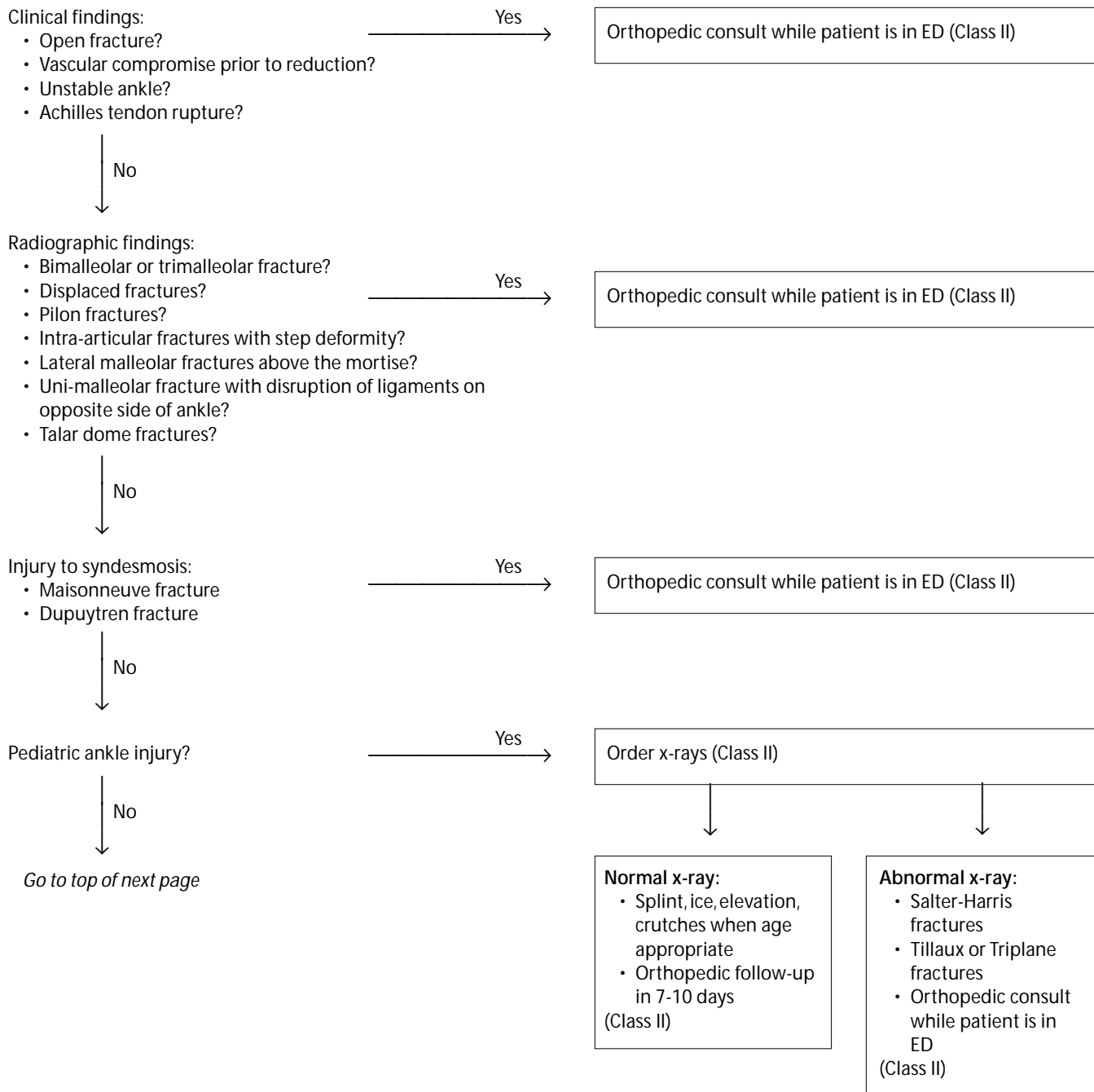


The **evidence for recommendations** is graded using the following scale. For complete definitions, see back page. **Class I:** Definitely recommended. Definitive, excellent evidence provides support. **Class II:** Acceptable and useful. Good evidence provides support. **Class III:** May be acceptable, possibly useful. Fair-to-good evidence provides support. **Indeterminate:** Continuing area of research.

This clinical pathway is intended to supplement, rather than substitute for, professional judgment and may be changed depending upon a patient's individual needs. Failure to comply with this pathway does not represent a breach of the standard of care.

Copyright © 2002 EB Practice, LLC. EB Practice, LLC (1-800-249-5770) grants each subscriber limited copying privileges for educational distribution within your facility or program. Commercial distribution to promote any product or service is strictly prohibited.

Clinical Pathway: Management Of Ankle Injuries

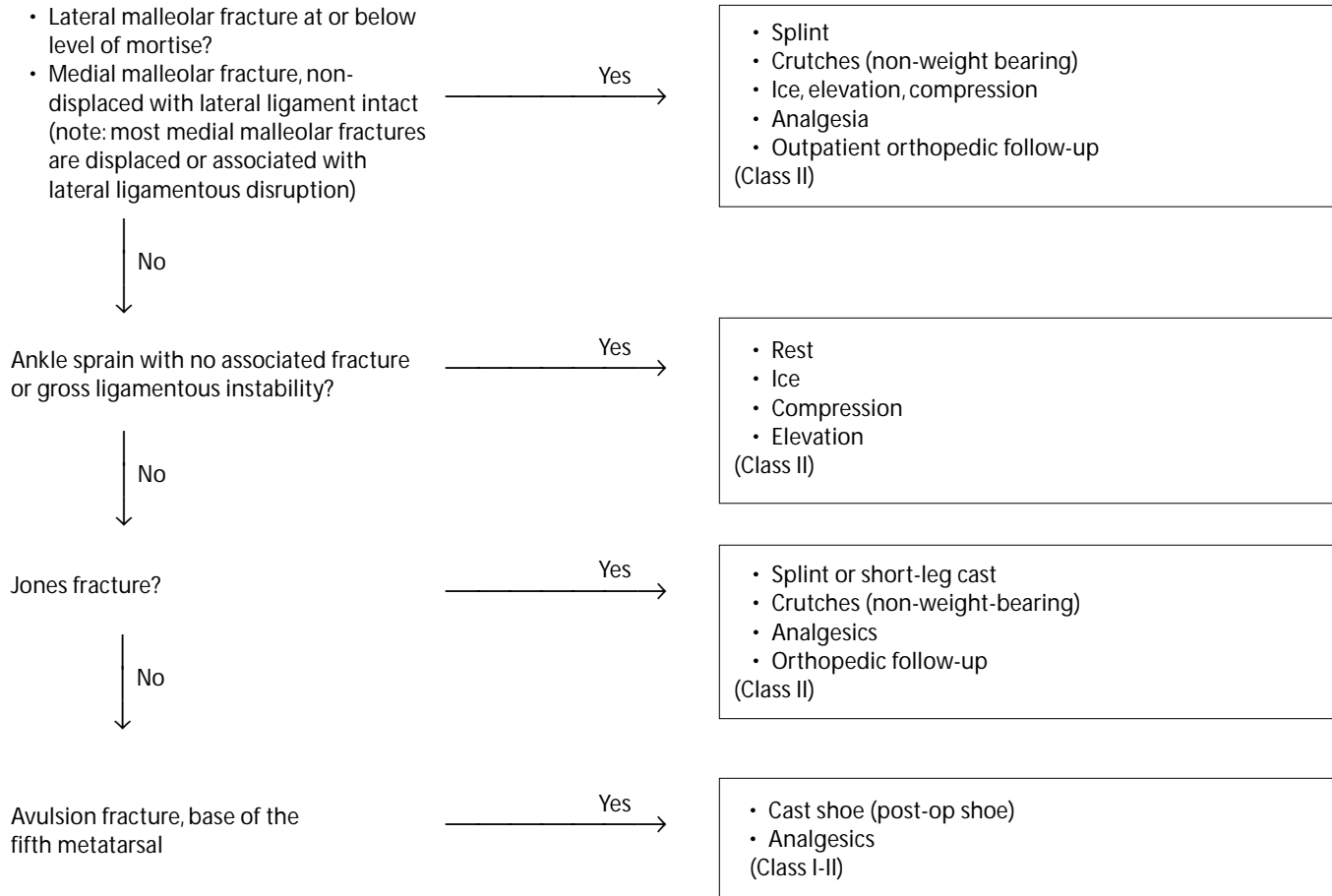


The **evidence for recommendations** is graded using the following scale. For complete definitions, see back page. **Class I:** Definitely recommended. Definitive, excellent evidence provides support. **Class II:** Acceptable and useful. Good evidence provides support. **Class III:** May be acceptable, possibly useful. Fair-to-good evidence provides support. **Indeterminate:** Continuing area of research.

This clinical pathway is intended to supplement, rather than substitute for, professional judgment and may be changed depending upon a patient's individual needs. Failure to comply with this pathway does not represent a breach of the standard of care.

Copyright © 2002 EB Practice, LLC. EB Practice, LLC (1-800-249-5770) grants each subscriber limited copying privileges for educational distribution within your facility or program. Commercial distribution to promote any product or service is strictly prohibited.

Clinical Pathway: Management Of Ankle Injuries (continued)



The **evidence for recommendations** is graded using the following scale. For complete definitions, see back page. **Class I:** Definitely recommended. Definitive, excellent evidence provides support. **Class II:** Acceptable and useful. Good evidence provides support. **Class III:** May be acceptable, possibly useful. Fair-to-good evidence provides support. **Indeterminate:** Continuing area of research.

This clinical pathway is intended to supplement, rather than substitute for, professional judgment and may be changed depending upon a patient's individual needs. Failure to comply with this pathway does not represent a breach of the standard of care.

Copyright © 2002 EB Practice, LLC. EB Practice, LLC (1-800-249-5770) grants each subscriber limited copying privileges for educational distribution within your facility or program. Commercial distribution to promote any product or service is strictly prohibited.

Continued from page 13

the medial clear space is suggestive of deltoid ligament rupture.¹⁰⁰ (See **Figure 11** on page 13.)

ED management of isolated deltoid ligament tears involves nonoperative techniques such as splinting, ambulation with crutches, and the RICE regimen in most cases.^{100,112} However, since injury to the deltoid ligament rarely occurs in isolation, carefully evaluate such patients for other injuries. Operative repair of the

deltoid ligament is generally reserved for those patients who exhibit joint instability or malalignment of the talus within the mortise after attempts to reestablish correct anatomic alignment have failed.

External Rotation Injuries

Syndesmosis Sprains

Forceful external rotation (SE or PE) accounts for the majority of distal tibiofibular syndesmosis sprains.

Ten Excuses That Don't Work In Court

1. "He only had a dislocated ankle—how was I supposed to know he also had a broken neck?"

Extremity pain may mask symptoms of another, more serious injury. Patients who sustain significant trauma should have their cervical spine cleared radiographically unless there are no distracting injuries, the patient is neurologically intact, there is no posterior midline tenderness, and there is a normal mental status without evidence of intoxication.

2. "The patient said his ankle hurt—not his knee."

Whenever a patient complains of ankle pain, the physician must palpate the proximal fibula and, if it's tender, order leg or knee films.

3. "The patient only complained of ankle pain. If his foot was broken, he should have said something."

Fractures of the navicular and the base of the fifth metatarsal often mimic ankle sprains. Palpation of the navicular and base of the fifth metatarsal is part of the routine physical examination for patients with ankle pain. (See also excuse #2.)

4. "Our orthopedists don't like us to do reductions. I got the x-rays and called the ortho guy, but he was busy, so I had to wait for his back-up. Finally he drove over from his office and reduced the ankle. Besides, the patient's foot was only slightly blue on arrival."

A patient with a dislocated ankle and neurovascular compromise cannot wait for the orthopedist; he needs a good emergency physician and an immediate reduction.

5. "I correctly diagnosed the pilon fracture—I'm sure I would have picked up the fractured body of L4 if the patient hadn't mentioned the history of chronic low back pain. Furthermore, he didn't say anything about heel pain."

Knowledge of the mechanism of injury—in this case, axial loading—suggests a predictable pattern of injury. It should prompt a targeted search for associated pathology (in this case, a burst fracture of L5 and a shattered calcaneus).

6. "We always use a cast shoe for fractures at the base of the fifth metatarsal. I can't believe the fellow had a non-union; everyone does well with that injury."

Someone is confused here. An *avulsion fracture* of the base of the fifth metatarsal (proximal to the level of the distal cuboid) gets sympathy and a post-op boot. A *Jones fracture* (distal to the level of the distal cuboid) needs a non-weight bearing cast for six weeks and orthopedic follow-up.

7. "He must have ruptured his Achilles tendon after I saw him. In the ED, he was able to bear weight for four steps. He could even wiggle his foot up and down."

Unlike the Thompson squeeze test, the "wiggle test" is not part of the sophisticated ankle examination. Patients with Achilles tendon rupture can still plantar flex their foot. Do the right test.

8. "The patient only had a sprain, so I discharged him with a compression dressing."

This patient had a widened medial clear space and no overlap of the tibia and fibula on the AP ankle view. If it had been performed, the squeeze test would have been positive. Higher-grade sprains (including this syndesmotic injury) should be rigidly immobilized in a splint. An unstable mortise mandates orthopedic consultation in the ED.

9. "The child had a lot of swelling and pain, but the x-rays were negative, so I sent her home with an Ace wrap."

Salter-Harris fractures may have very subtle x-ray findings, or none at all. Bony tenderness over a malleolus in a child with open growth plates equals a fracture until proven otherwise in follow-up.

10. "The patient only had an ankle effusion on x-ray, so I didn't think that follow-up with a specialist was necessary."

Patients with a significant ankle effusion have a high likelihood of an occult fracture. Such patients need follow-up care with an orthopedist (and possibly an outpatient CT). ▲

Although these injuries are much less common than lateral ankle sprains,^{25,72,113} significant disability can occur if the patient does not receive appropriate treatment and follow-up.¹⁰⁰ Injury to the tibiofibular syndesmosis is suggested by a positive squeeze test or external rotation test. On plain radiographs, widening of the medial clear space strongly suggests syndesmosis disruption;^{23,100} however, non-weight-bearing views are often negative. Other suggestive radiographic findings include: 1) lateral clear space greater than 6 mm on AP or mortise views; and 2) tibiofibular overlap less than 6 mm on AP view or less than 1-2 mm on mortise view.^{32,99,100}

Grade I syndesmosis sprains without fracture are typically associated with a stable joint and can be managed conservatively in the ED with application of a splint and weight-bearing with crutches.^{25,109} Patients should adhere to a RICE regimen with a gradual return to full weight-bearing as tolerated, and receive instructions to follow up with an orthopedist within two weeks.¹⁰⁰ Grade II and III sprains with and without fracture present with greater degrees of diastasis of the distal tibiofibular joint. Orthopedic consultation and, ultimately, surgical repair are required.¹⁰⁰

Maisonneuve Fracture

The Maisonneuve variant of the syndesmosis sprain features a proximal fibular fracture in association with rupture of the deltoid and syndesmotom ligaments (DW type C). Typically, these patients are unable to bear weight and exhibit tenderness over the proximal fibula and pain at the ankle when the examiner performs the squeeze test. It is essential that the emergency physician carefully palpate the entire fibula looking for a Maisonneuve fracture in any patient with an ankle injury. This fracture is unstable, and several sources advocate open reduction and internal fixation.^{23,100}

Eversion/External Rotation Injuries

Fractures

Forced external rotation with either supination or pronation (SE and PE) cause low fractures of the medial malleolus or deltoid ligament tears, AITFL and PITFL tears, and fractures of the lateral malleolus. The two groups differ with respect to the type and location of the malleolar fracture: SE forces produce spiral fractures of the lateral malleolus *at* the level of the mortise, whereas PE forces produce high fractures of the fibula *above* the mortise. Fractures associated with SE and PE forces are essentially the same as those classified as Weber type B and C, respectively, which feature medial malleolar avulsion fractures associated with disruption of the inferior tibiofibular syndesmosis (AITFL and PITFL) and either a low (*at* the mortise [type B]) or high (*above* the mortise [type C]) fracture of the fibula. (See **Figure 12** and **Figure 13** on page 20.) Additionally, consider the presence of a Maisonneuve fracture of the proximal fibula in patients who sustain

this mechanism of injury.

With regard to treatment, unless the patient has an isolated lateral malleolar fracture, LH SE and PE fractures (Weber type B and C) are operatively managed and require orthopedic consultation.

Axial Loading Injuries

This mechanism of injury typically occurs in patients who land on their feet after falling from a height, are applying the brake when involved in a front-end motor vehicle collision, or take a forceful misstep while climbing stairs. The forces involved in axial loading produce pronation and dorsiflexion of the foot and ankle, respectively, as the talus is driven into the tibia. The classic axial loading injury is the tibial plafond (or pilon) fracture, which is often comminuted.

An axial loading mechanism may also rupture the Achilles tendon. Patients with rupture of the Achilles tendon require immobilization in plantar flexion, non-weight bearing, and orthopedic referral.^{67,69}

*“He’s the best physician that knows
the worthlessness of the most medicines.”
—Benjamin Franklin*

Management

The absence of fracture on x-ray does not rule out the presence of a significant injury. Depending on their clinical examination, some patients with negative films may require splinting, casting, orthopedic consultation, or even surgery. Conversely, the presence of any positive finding on x-ray, such as bony malalignment, avulsion fracture, or effusion,^{101,102} should prompt a search for other fractures and soft-tissue injuries.

In general, immobilize all ankle fractures that are discovered during the evaluation of ED patients. Cases of stable fracture patterns that preserve the structural integrity of the ring (i.e., nondisplaced unimalleolar fractures without opposing or syndesmotom ligamentous injury) may be discharged with non-weight-bearing instructions and early orthopedic follow-up. Orthopedic consultation in the ED (either in person or via telephone) is warranted for displaced fractures, open fractures, unimalleolar fractures with opposing or syndesmotom ligamentous injury, and fibular fractures proximal to the ankle mortise. Other injuries that require consultation include bimalleolar fractures, trimalleolar fractures, intra-articular fractures with step deformity, and pilon fractures.¹¹⁰ Likewise, patients with growth plate injuries may heal poorly and require orthopedic consultation prior to discharge.

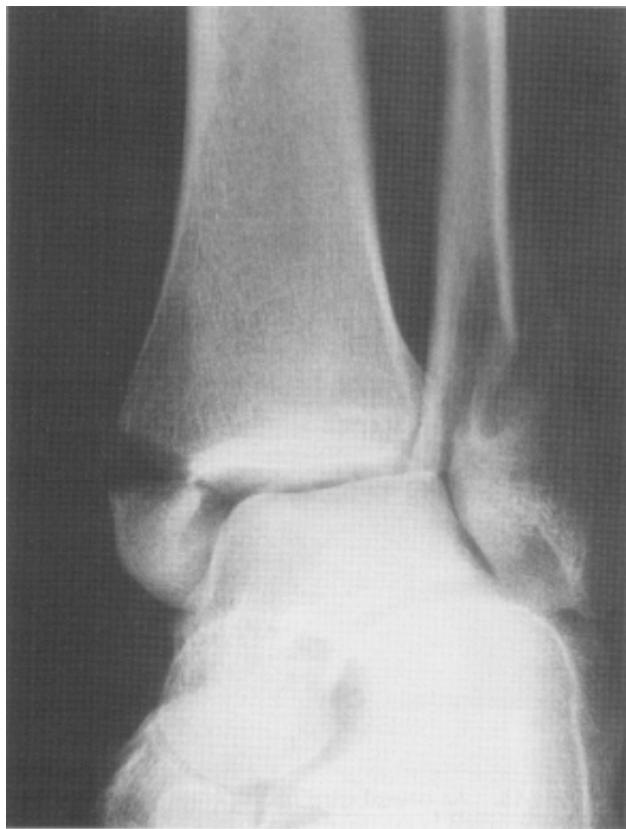Ankle Sprains

Immobilization

While the optimal duration of immobilization is unknown, early return to “activity as tolerated” may be the best strategy in the rehabilitation of the ankle. In

one randomized study of 82 patients, the early mobilization group received an elastic wrap for two days followed by functional bracing for eight days. Two days after injury, this group began weight bearing and an ankle rehabilitation program. Patients in the immobilization group were placed in a non-weight-bearing plaster splint for 10 days followed by weight bearing and the same rehabilitation program. The authors found that in patients with first-time lateral ankle sprains, early mobilization permitted earlier return to work and was more comfortable for patients.¹¹⁴ In a quasi-meta-analysis, authors evaluated randomized and quasi-randomized clinical trials involving adults with acute ankle sprains, which compared immobilization to early mobilization for the treatment of lateral ankle sprains.¹¹⁵ The authors concluded that functional treatment (early mobilization) should be encouraged and that immobilization, if

Figure 12. This bimalleolar fracture is caused by supination-external rotation forces. There is a transverse medial malleolar fracture associated with a spiral fracture of the fibula occurring at the level of the mortise. This injury is classified as Lauge-Hansen SE grade 4 or Danis-Weber type B and is unstable.



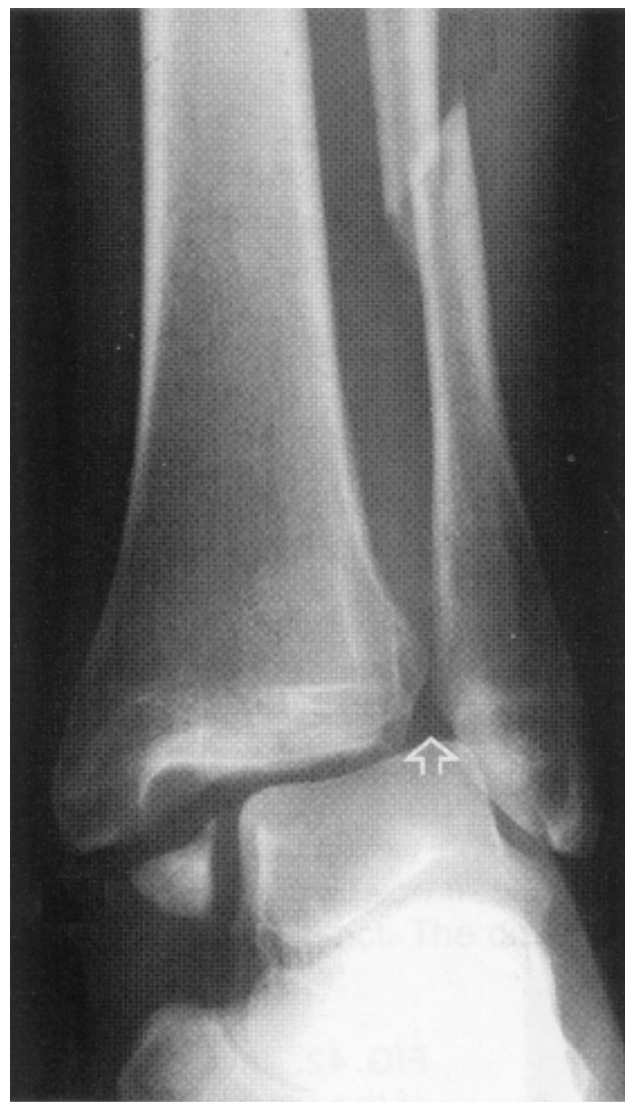Reproduced with permission from: Williamson B, Schwartz DT. The ankle and leg. In: Schwartz DT, Reisdorff EJ, eds. *Emergency Radiology*. New York: McGraw-Hill; 2000:172. Figure 9-18a.

necessary, should be restricted to certain patients and for short time periods.

Splints And Wraps

Another concern involves how to immobilize. Options include an Ace wrap, compression dressing, ankle taping, plaster splints, and a variety of prefabricated

Figure 13. This bimalleolar fracture is caused by pronation-external rotation forces. There is a transverse medial malleolar fracture associated with a spiral fracture of the fibula occurring above the level of the mortise. There is no tibiofibular overlap indicating disruption of the syndesmosis (open arrow). This injury is classified as Lauge-Hansen PE grade 4 or Danis-Weber type C and is unstable.



Reproduced with permission from: Harris JH. Ankle. In: Harris JH, Harris WH, eds. *The Radiology of Emergency Medicine*. Philadelphia: Lippincott, Williams & Wilkins; 2000:857. Figure 38b.

splinting devices. The literature comparing these devices is mixed. In one study, an Air-Stirrup ankle brace was compared to a compression bandage in 73 patients with grade II and III ankle sprains. The authors concluded that the group treated with the Air-Stirrup ankle brace was more mobile in the initial phase of rehabilitation and had a shorter sick leave, resulting in socioeconomic savings.¹¹⁶ However, another randomized clinical trial showed that patients placed in an elastic wrap performed as well as those in the Air-Stirrup.¹¹⁷ Yet another study used high-speed cameras to show that none of the braces tested—a semi-rigid stirrup (AirCast Sport Stirrup), semi-rigid modified stirrup (Malleoloc), or a soft, sleeve design (Swede-O)—restricted inversion compared to an unbraced ankle during sideward cutting maneuvers.¹¹⁸ Other studies suggest that functional outcome is not significantly influenced by the choice of either a compression bandage or air-cushioned ankle brace.¹¹⁹

Unimalleolar Fractures

Isolated lateral malleolar fractures are common and, for the most part, can be managed non-operatively. Avulsion fractures of the lateral malleolus in association with lateral ligament sprains can be immobilized in a splint, and the patient should be instructed to non-weight bear with crutches.¹²⁰ Adjunctive therapies include analgesia, ice, elevation of the extremity, and the provision of timely follow-up with an orthopedist. Likewise, isolated transverse fractures of the lateral malleolus *below* the level of the mortise (LH SA1 or Weber type A) are typically stable and are managed non-operatively with initial immobilization in a splint, followed by casting for a period of 6-8 weeks, including non-weight bearing for at least the first three weeks.¹¹⁰

Non-displaced isolated spiral fractures of the lateral malleolus that occur *at* the level of the mortise (LH SE or Weber type B) are often managed non-operatively by applying a splint or cast for 6-8 weeks. Orthopedic consultation in the ED is recommended if there is widening of the medial clear space (since this suggests a disruption of the deltoid ligament or syndesmosis).¹¹⁰

In contrast, isolated spiral fractures of the fibula above the mortise (LH PE or Weber type C) are associated with a ruptured syndesmosis. Orthopedic consultation in the ED is important, as these injuries generally require internal fixation to optimize outcome.¹¹⁰

Isolated medial malleolar fractures are uncommon and usually occur with associated injuries to other structures. If the medial malleolar fracture is truly nondisplaced and the lateral components of the joint are intact, these fractures may be managed non-operatively, initially with splinting and then casting for 6-8 weeks, non-weight bearing for the first three weeks, and early orthopedic follow-up.¹¹⁰ Displaced medial malleolar fractures require open reduction and internal fixation,¹²¹

as treatment by closed means yields a nonunion rate ranging from 5%-15%.¹²²

Splinting Techniques

The emergency physician should be able to construct a splint or compression dressing to immobilize any significant ligamentous injury or fracture. There are several theoretical benefits to splinting, such as reduction of pain, avoidance of further injury, maintenance of anatomic alignment, and prevention of wound dehiscence, all of which function to augment the healing process. Today, there are many commercial plaster and fiberglass products that simplify the process, allowing the emergency physician to apply a splint effectively and efficiently.

The severity of injury will determine the degree of immobilization required. In the case of an isolated, low-grade sprain, a compression dressing crafted of soft roll and elastic bandages is sufficient to give support and reduce swelling. This “compression” portion of the RICE regimen should be in every emergency physician’s armamentarium. In contrast, all ankle fractures (with the exception of isolated lateral malleolar avulsions) should be immobilized in a rigid splint prior to discharge or while awaiting orthopedic consultation.

Jones Compression Dressing

This soft dressing does not provide immobilization and is only appropriate for low-grade sprains. The soft roll that forms the under layer should start distally around the foot and be wrapped proximally to a point above the injury. Each wrap should overlap the previous one by roughly 25%-50%. Over this layer, an elastic bandage is wrapped using the same technique. If additional protection is required, the process may be repeated with a second or third soft roll covered by another elastic bandage.

Posterior Splint

This is the most common of all splints applied in the ED. It offers rigid immobilization for high-grade sprains and ankle fractures and can be applied quickly and easily by the emergency physician. It is crafted from 4- or 6-inch-wide plaster strips or fiberglass with an under layer of padding. With the patient prone and the knee flexed at 90°, the splint should extend from the plantar surface overlying the metatarsal heads across the heel and posterior leg to the level of the fibular head. If plaster is to be used, roughly 15-20 layers should be applied to minimize the likelihood of cracking, which tends to occur during weight-bearing.¹²³ If partial weight-bearing is allowed, the ankle should be immobilized at 90° to create a flat walking surface. The moist plaster or fiberglass is held in place with elastic bandages, and molding is required around the edges and ankle area to ensure adequate immobilization.¹²⁴

While posterior splints are popular, they have a strong tendency to develop a “hinge” just above the heel within days of application.¹²³

Anterior Splint

This splint should not be used alone as it does not provide adequate immobilization of the ankle joint. Rather, it is used in conjunction with a posterior splint, creating a bivalve effect. It is fashioned from the same materials as the posterior splint, only with fewer layers, and it can be several centimeters shorter than its posterior counterpart. It should extend from the dorsal aspect of the midfoot proximally to the mid shin. Both the anterior and posterior splints are wrapped with elastic bandages and molded accordingly.¹²⁴

Sugar-Tong (Stirrup) Splint

This splint can be used either alone or in conjunction with the anterior or posterior splint to immobilize high-grade sprains or ankle fractures. *It is crafted from the same materials but may offer greater immobilization and is less likely to crack compared to the posterior splint.*¹²³ The sugar-tong passes under the plantar surface of the foot and proximally over the medial and lateral aspects of the leg to the level of the fibular head. It is covered with elastic bandages and molded to fit the contours of the extremity.¹²⁴

Pediatric Considerations

Because of the relatively greater strength of the ligaments during childhood, children are far more likely to sustain fractures through the epiphyseal growth plate than tear a ligament. Ankle sprains are uncommon in the pediatric population, and the emergency physician should be wary of this diagnosis.

Salter-Harris classifies growth plate injuries into types I-V based on the anatomic location of the fracture plane. (See Figure 14.) Initial x-rays may be normal or feature subtle findings such as soft-tissue swelling, avulsion fragments, or plate separation. Even without radiographic evidence of fracture, empirically treat the child as if a fracture were present—immobilize and refer. Failure to manage a physeal injury appropriately may result in growth arrest and permanent disability.

Although the original Ottawa Ankle Rules were developed and validated in adult patients 18-55 years old,^{3,53,58,88} several studies support the effectiveness of the Ottawa Ankle Rules in children.¹²⁵⁻¹²⁸

In pediatric patients, the unfused apophysis of the base of the fifth metatarsal may be mistaken for a fracture owing to its location and characteristic x-ray appearance. Both the Jones and pseudo-Jones fractures are *transversely oriented* with fracture lines that cross the long axis of the foot, in contrast to the radiographic appearance of the apophyseal growth plate, which is oriented *parallel* to the long axis of the foot.

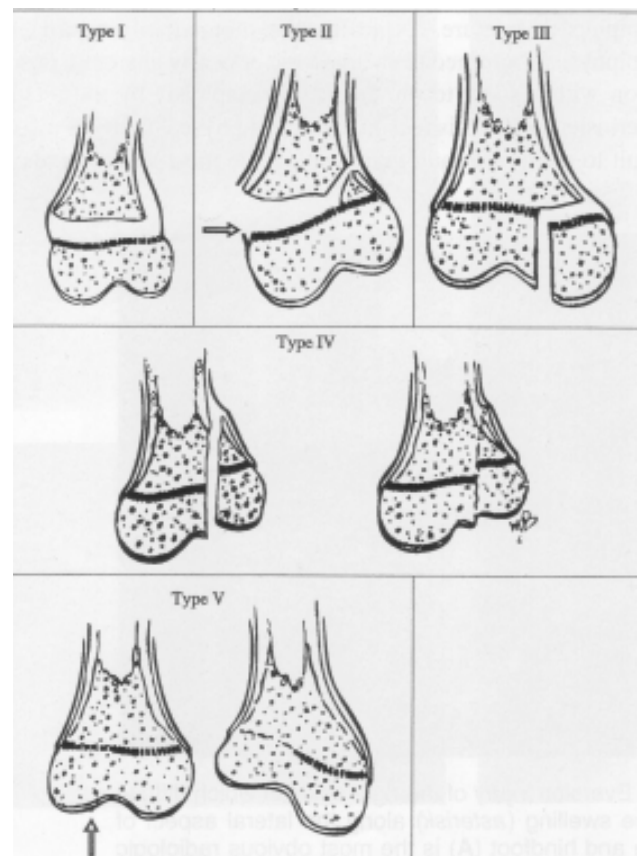
“There is nothing more difficult to take in hand, more perilous to conduct, or more uncertain in its success, than to take the lead in the introduction of a new order to things.”—Niccolo Machiavelli

Controversies/Cutting Edge

Over the past decade, falling costs and increased availability of CT and MRI have created new possibilities for ankle imaging. While the Ottawa Ankle Rules are nearly 100% sensitive for fracture fragments of greater than 3 mm, they are insensitive for smaller, “occult” injuries. Plain films have similar limitations.

In a study undertaken in British Columbia, 34 patients with ankle effusions and no fracture visible on plain film were subject to CT. On physical examination, all 34 patients had ecchymosis and edema overlying two or more major stabilizing ligaments of the ankle but did not necessarily fulfill Ottawa Ankle Rules criteria. Thirty-five percent had fractures visualized on CT.¹²⁹ ED management was influenced by the CT results, with 10 of the 12 patients receiving plaster

Figure 14. Salter-Harris classification of growth plate injuries.



Reproduced with permission from: Rang M. The growth plate and its diseases. In: Rockwood CA Jr, Wilkins KE, King RE, eds. *Fractures in Children*. 3rd ed. Philadelphia: Lippencott-Raven Publishers; 1991:128.

immobilization and two undergoing open reduction and internal fixation.

This small study cannot provide decisive information regarding the cost-effectiveness of routine CT in those with a suggestive physical examination and a radiographic effusion. At the present time, such patients warrant rigid immobilization and orthopedic consultation.

Although MRI has the ability to accurately identify collateral and syndesmotic ligamentous injury,¹³⁰ it should be ordered on an outpatient basis at the discretion of the orthopedic consultant.

Summary

Patients with chief complaints of "ankle pain" contribute significantly to overall ED volume, are exposed to significant radiation, and sustain long ED waits. All patients require a thorough history and physical examination. Knowledge of ankle anatomy and force vectors will help focus the clinical examination.

Roughly 10% of all ED x-rays are of the ankle,¹³¹ and yet 85%-90% of these films are negative. The Ottawa Ankle Rules are currently one of the most extensively studied and widely accepted clinical decision rules in clinical practice. While they can help determine who should undergo ankle radiography, these rules should not be used to differentiate between stable and unstable injury patterns.

One of the most important determinations in dealing with ankle injuries involves whether the injury is stable or unstable. This single issue drives all further management. Fracture or sprain, x-ray or no x-ray, in ED consultation or outpatient follow-up, the emergency physician must provide a level of care that is appropriate for the severity of injury. ▲

References

Evidence-based medicine requires a critical appraisal of the literature based upon study methodology and number of subjects. Not all references are equally robust. The findings of a large, prospective, randomized, and blinded trial should carry more weight than a case report.

To help the reader judge the strength of each reference, pertinent information about the study, such as the type of study and the number of patients in the study, will be included in bold type following the reference, where available. In addition, the most informative references cited in the paper, as determined by the authors, will be noted by an asterisk (*) next to the number of the reference.

- 1.* Sujitkumar P, Hadfield JM, Yates DW. Sprain or fracture? An analysis of 2000 ankle injuries. *Arch Emerg Med* 1986;3:101-106. **(Retrospective; 2140 patients aged 12 or older)**
2. Rubin A, Sallis R. Evaluation and diagnosis of ankle injuries. *Am Fam Physician* 1996;54:1609-1618. **(Review)**
- 3.* Stiell IG, Greenberg GH, McKnight RD, et al. Decision rules

for the use of radiography in acute ankle injuries. Refinement and prospective validation. *JAMA* 1993;269:1127-1132.

- (Regression analysis; 1032 patients; Prospective validation, 453 patients aged 18 years or older)**
4. Birrer RB, Fani-Salek MH, Totten VY, et al. Managing ankle injuries in the emergency department. *J Emerg Med* 1999;17:651-660. **(Review)**
5. Smith RW, Nelson DR. Fractures and other injuries from falls after an ice storm. *Am J Emerg Med* 1998;16:52-55. **(Retrospective, observational; 327 injuries)**
6. Prebble TB, Chyou PH, Wittman L, et al. Basketball injuries in a rural area. *WMJ* 1999;98:22-24. **(Comparative; 1189 basketball injuries)**
7. Fahlstrom M, Bjornstig U, Lorentzon R. Acute badminton injuries. *Scand J Med Sci Sports* 1998;8:145-148. **(Retrospective)**
8. Kirkpatrick DP, Hunter RE, Janes PC, et al. The snowboarder's foot and ankle. *Am J Sports Med* 1998;26:271-277. **(Prospective, observational; 3213 snowboarding injuries)**
9. Trevino SG, Alvarez R. The spectrum of lower leg injuries in skiing. *Clin Sports Med* 1982;1:263-276.
10. Briner WW Jr, Carr DE, Lavery KM. Anteroinferior tibiofibular ligament injury: not just another ankle sprain. *Physician Sports Med* 1989;17:63-69. **(Review)**
11. Birrer RB. Ankle injuries and the family physician. *J Am Board Fam Pract* 1988;1:274-281. **(Review)**
12. Hamilton WG. Foot and ankle injuries in dancers. *Clin Sports Med* 1988;7:143-173. **(Review)**
13. Macintyre J, Joy E. Foot and ankle injuries in dance. *Clin Sports Med* 2000;19:351-358. **(Review)**
14. Wilson LS Jr, Mizel MS, Michelson JD. Foot and ankle injuries in motor vehicle accidents. *Foot Ankle Int* 2001;22:649-652. **(Retrospective; 2248 patients)**
15. As cited in Mohler K, ed. *Webster's Electronic Quotabase*. 1994.
16. Rasmussen O. Stability of the ankle joint: analysis of the function and traumatology of the ankle ligaments. *Acta Orthop Scand Suppl* 1985;211:1-75.
17. Seto JL, Brewster CE. Treatment approaches following foot and ankle injuries. *Clin Sports Med* 1994;13:695-718. **(Review)**
18. Michelson JD, Solocoff D, Waldman B, et al. Ankle fractures: the Lauge-Hansen classification revisited. *Clin Orthop* 1997;345:198-205. **(Observational; 32 cadaveric ankles)**
- 19.* Liu SH, Williams JJ. Lateral ankle sprains and instability problems. *Clin Sports Med* 1994;13:793-809. **(Review)**
20. Garrick JG. The frequency of injury, mechanism of injury, and epidemiology of ankle sprains. *Am J Sports Med* 1977;5:241-242.
21. Garrick JG, Requa RK. The epidemiology of foot and ankle injuries in sports. *Clin Sports Med* 1988;7:29-36. **(Retrospective; 16,754 injuries)**
22. Kannus P, Renstrom P. Current concepts review: treatment for acute tears of the lateral ligaments of the ankle; operation, cast, or early controlled mobilization. *J Bone Joint Surg Am* 1991;73:305-312. **(Review)**
23. Donatto KC. Ankle fractures and syndesmosis injuries. *Orthop Clin North Am* 2001;32:79-90. **(Review)**
24. Michelson JD, Ahn UM, Helgemo SL. Motion of the ankle in a simulated supination-external rotation fracture model. *J Bone Joint Surg Am* 1996;78A:1024-1031. **(Observational; 13**

below-the-knee amputation specimens)

25. Hopkinson WJ, St. Pierre P, Ryan JB, et al. Syndesmosis sprains of the ankle. *Foot Ankle* 1990;10:325-330. **(Retrospective; 1344 ankle sprains)**
26. Eckert WR, Davis EA Jr. Acute rupture of the peroneal retinaculum. *J Bone Joint Surg Am* 1976;58A:670-673. **(Prospective, cohort; 73 surgically explored skiers)**
27. Moore KL. The lower limb. In: Moore KL, ed. *Clinically Oriented Anatomy*. Baltimore: Williams & Wilkins; 1992:373-500. **(Textbook)**
28. Jarvinen TA, Kannus P, Paavola M, et al. Achilles tendon injuries. *Curr Opin Rheumatol* 2001;13(2):150-155. **(Review; 31 references)**
29. Casparian JM, Luchi M, Moffat RE, et al. Quinolones and tendon ruptures. *South Med J* 2000 May;93(5):488-491. **(Review; 15 references)**
30. As cited in: *The Ultimate Success Quotations Library*. 1997.
31. Lauge-Hansen N. Fractures of the ankle. II. combined experimental-surgical and experimental roentgenologic investigations. *Arch Surg* 1950;60:957-985. **(Review)**
32. Williamson B, Schwartz DT. The ankle and leg. In: Schwartz DT, Reisdorff EJ, eds. *Emergency Radiology*. New York: McGraw-Hill; 2000:157-184. **(Textbook chapter)**
33. Bladin C, Giddings P, Robinson M. Australian snowboard injury data base study: a four-year prospective study. *Am J Sports Med* 1993;21:701-704. **(Prospective, observational; 276 injuries)**
34. Nicholas R, Hadley J, Paul C, et al. "Snowboarder's fracture": fracture of the lateral process of the talus. *J Am Board Fam Med* 1994;7:130-133. **(Review)**
35. McCrory P, Bladin C. Fractures of the lateral process of the talus: a clinical review. "Snowboarder's ankle." *Clin J Sports Med* 1996;6:124-128. **(Review)**
36. Ganong RB, Heneveld EH, Beranek SR, et al. Snowboarding injuries: a report on 415 patients. *Phys Sports Med* 1992;20:114-122. **(Patient questionnaire; 415 respondents aged 9 to 46 years)**
37. Dimon JH. Isolated displaced fractures of the posterior facet of the talus. *J Bone Joint Surg Am* 1961;43A:275-281. **(Case report; 3 patients)**
38. Mukherjee SK, Pringle PM, Baxter AD. Fracture of the lateral process of the talus: a report of thirteen cases. *J Bone Joint Surg Br* 1974;56B:263-273. **(Case report; 13 patients)**
39. Ebraheim NA, Skie MC, Podeszwa DA, et al. Evaluation of process fractures of the talus using computed tomography. *J Orthop Trauma* 1994;8:332-337. **(Prospective, cohort; 10 patients)**
40. Noble J, Royale SG. Fracture of the lateral process of the talus: CT scan diagnosis. *Br J Sports Med* 1992;26:245-246. **(Case report)**
41. Paul CC, Janes PC. The snowboarder's talus fracture. In: Mote CD, Johnson RJ, Hauser W, et al, eds. *Skating Trauma and Safety*. Philadelphia: ASTM; 1996:388-393. **(Textbook chapter)**
42. Sirkin M, Sanders R. The treatment of pilon fractures. *Orthop Clin North Am* 2001;32:91-102. **(Review)**
43. Tornetta P 3rd, Gorup J. Axial computed tomography of pilon fractures. *Clin Orthop* 1996;323:273-276. **(Evaluation; 22 patients)**
44. Watson JT, Moed BR, Karges DE. Pilon fractures: treatment protocol based on severity of soft tissue injury. *Clin Orthop* 2000;375:78-90. **(Prospective, comparative; 107 patients)**
45. Michael JA, Steill IG. Ankle injuries. In: Tintinalli JE, Kelen GD, Stapczynski JS, eds. *Emergency Medicine: A Comprehensive Study Guide*. New York: McGraw-Hill; 2000:1825-1833. **(Textbook chapter)**
46. Harris JH. Ankle. In: Harris JH, Harris WH, eds. *The Radiology of Emergency Medicine*. Philadelphia: Lippincott Williams & Wilkins; 2000:839-866. **(Textbook chapter)**
47. Steinlauf SD. Juvenile Tillaux fracture simulating syndesmosis separation: a case report. *Foot Ankle Int* 1998;19:332-335. **(Case report; 1 patient)**
48. Jones R. Fractures of the base of the fifth metatarsal bone by indirect violence. *Ann Surg* 1902;35:697-702. **(Review)**
49. McNamara R. Management of common dislocations. In: Roberts JR, Hedges JR, eds. *Clinical Procedures in Emergency Medicine*. Philadelphia: WB Saunders Company; 1998:818-852. **(Textbook chapter)**
50. Parenteau CS. Foot-ankle injuries: influence of crash location, seating position and age. *Accid Anal Prev* 1996;28:607-617. **(Epidemiology study; 805 foot-ankle injuries out of 57,949 car occupant injuries)**
51. Welch LS, Hunting KL, Anderson JT. Injury surveillance in construction: injuries to laborers. *J Occup Environ Med* 2000;42:898-905. **(Retrospective, observational; 965 laborers)**
52. Wright IC. The influence of foot positioning on ankle sprains. *J Biomech* 2000;33:513-519. **(Comparative; 10 patients)**
- 53.* Stiell IG, Greenberg GH, McKnight RD, et al. A study to develop clinical decision rules for the use of radiography in acute ankle injuries. *Ann Emerg Med* 1992;21:384-390. **(Regression analysis; 750 patients)**
- 54.* Stiell IG, McDowell I, Nair RC, et al. Use of radiography in acute ankle injuries: physicians' attitudes and practice. *Can Med Assoc J* 1992;147:1671-1678. **(Prospective survey of retrospective data; 1831 patients aged 18 years or older)**
55. Stricker PR, Spindler KP, Gautier KB. Prospective evaluation of history and physical examination: variables to determine radiography in acute ankle injuries. *Clin J Sport Med* 1998;8:209-214. **(Regression analysis on prospective data; 74 patients)**
56. Blotter RH, Connolly E, Wasan A, et al. Acute complications in the operative treatment of isolated ankle fractures in patients with diabetes mellitus. *Foot Ankle Int* 1999;20:687-694. **(Retrospective; 21 patients)**
57. Bibbo C, Lin SS, Beam HA, et al. Complications of ankle fractures in diabetic patients. *Orthop Clin North Am* 2001;32:113-133. **(Review)**
- 58.* Stiell IG, McKnight RD, Greenberg GH, et al. Implementation of the Ottawa ankle rules. *JAMA* 1994;271:827-832. **(Retrospective validation, controlled; 2342 patients aged 18 years or older)**
59. Reid PM, Aggarwal AK, Browning C, et al. The relevance of hearing a crack in ankle injuries. *J Accid Emerg Med* 1996;13:278-279. **(Questionnaire; 464 patients)**
- 60.* Fujii T, Luo ZP, Kitaoka HB, et al. The manual stress test may not be sufficient to differentiate ankle ligament injuries. *Clin Biomech (Bristol, Avon)* 2000 Oct;15(8):619-623. **(Comparative)**
- 61.* van Dijk CN, Mol BW, Lim LS, et al. Diagnosis of ligament rupture of the ankle joint. Physical examination, arthrography, stress radiography and sonography compared in 160 patients after inversion trauma. *Acta Orthop Scand* 1996 Dec;67(6):566-570. **(Prospective; 160 patients)**
62. Frost HM, Hanson CA. Technique for testing the drawer

- sign in the ankle. *Clin Orthop* 1977;123:49-51. **(Review)**
63. Tohyama H, Beynon BD, Renstrom PA, et al. Biomechanical analysis of the ankle anterior drawer test for anterior talofibular ligament injuries. *J Orthop Res* 1995;13:609-614. **(Observational; 12 cadaveric ankle specimens)**
 64. Prins JG. Diagnosis and treatment of injury to the lateral ligament of the ankle: a comparative clinical study. *Acta Chir Scand* 1978;486(suppl):1-149. **(Comparative)**
 65. Birrer RB, Bordelon RL, Sammarco GL. Ankle: don't miss a sprain. *Patient Care* 1992;26:6-28. **(Review)**
 66. Anderson S. Evaluation and treatment of ankle sprains. *Comp Ther* 1996;22:30-38. **(Review)**
 - 67.* Wedmore IS, Charette J. Emergency department evaluation and treatment of ankle and foot injuries. *Emerg Med Clin North Am* 2000;18:85-113. **(Review)**
 68. As cited in: "A Week on the Concord and Merrimack Rivers" (1849), in *The Writings of Henry David Thoreau*, vol. 1, p. 110, Houghton Mifflin (1906).
 - 69.* Mafulli N. The clinical diagnosis of subcutaneous tear of the Achilles tendon: a prospective study in 174 patients. *Am J Sports Med* 1998;26:266-270. **(Prospective validation; 174 patients)**
 70. Copeland SA. Rupture of the Achilles tendon: a new clinical test. *Ann R Coll Surg Engl* 1990 Jul;72(4):270-271.
 71. Gratton MC, Salomone JA, Watson WA. Clinically significant radiograph misinterpretations at an emergency medicine residency program. *Ann Emerg Med* 1990;19:497-502. **(Prospective, comparative; 12,395 imaging studies)**
 72. Fallat L, Grimm DJ, Saracco JA. Sprained ankle syndrome: prevalence and analysis of 639 acute injuries. *J Foot Ankle Surg* 1998;37:280-285. **(Prospective, observational; 639 patients)**
 73. Garfield JS, Cantab MB. Is radiological examination of the twisted ankle necessary? *Lancet* 1960;2:1167-1169. **(Observational; 111 patients)**
 74. Abrams HL. Sounding board: the "overutilization" of x-rays. *N Engl J Med* 1979;300:1213-1216. **(Editorial)**
 75. Long AE. Radiographic decision-making by the emergency physician. *Emerg Med Clin North Am* 1985;3:437-446. **(Review)**
 76. Stiell IG, McKnight RD, Greenberg GH, et al. Interobserver agreement in the examination of acute ankle injury patients. *Am J Emerg Med* 1992;10:14-17. **(Prospective; 100 patients)**
 77. Kerr L, Kelly AM, Grant J, et al. Failed validation of a clinical decision rule for the use of radiography in acute ankle injury. *N Z Med J* 1994;107:294-295. **(Prospective validation; 350 patients)**
 78. Lucchesi GM, Jackson RE, Peacock WF, et al. Sensitivity of the Ottawa rules. *Ann Emerg Med* 1995;26:1-5. **(Prospective validation; 484 patients aged 18 years or older)**
 79. Anis AH, Stiell IG, Stewart DG, et al. Cost-effectiveness analysis of the Ottawa ankle rules. *Ann Emerg Med* 1995;26:422-428. **(Retrospective, cost analysis)**
 80. Heilicser B. Emergency medicine is not a Ford Pinto. *Ann Emerg Med* 1996;27:676. **(Letter)**
 81. Laupacis A, Stiell IG, Stewart D. Using the Ottawa ankle rules. *Ann Emerg Med* 1996;28:730-731. **(Letter)**
 - 82.* Auleley GR, Kerboul L, Durieux P, et al. Validation of the Ottawa ankle rules in France: a study in the surgical emergency department of a teaching hospital. *Ann Emerg Med* 1998;32:14-18. **(Prospective validation; 416 patients aged 18 years or older)**
 - 83.* Kaufman D, Leung J. Evaluation of the patient with extremity trauma: an evidence based approach. *Emerg Med Clin North Am* 1999;17:77-95. **(Review)**
 84. Singh-Ranger G, Marathias A. Comparison of current local practice and the Ottawa Ankle Rules to determine the need for radiography in acute ankle injury. *Accid Emerg Nurs* 1999;7:201-206. **(Prospective validation, comparison; 18 patients)**
 85. Philbin T, Donley BG. When do you x-ray ankle sprains in patients with acute ankle injuries? *Cleve Clin J Med* 2000;67:405-406,455. **(Review)**
 86. Graham ID, Steill IG, Laupacis A, et al. Awareness and use of the Ottawa ankle and knee rules in 5 countries: can publication alone be enough to change practice? *Ann Emerg Med* 2001;37:259-266. **(Cross-sectional, physician questionnaire; 1769 emergency physician respondents)**
 87. Pigman EC, Klug RK, Sanford S, et al. Evaluation of the Ottawa clinical decision rules for the use of radiography in acute ankle and midfoot injuries in the emergency department: an independent site assessment. *Ann Emerg Med* 1994;24:41-45. **(Prospective validation; 110 patients)**
 - 88.* Stiell IG, Wells G, Laupacis A, et al. Multicentre trial to introduce the Ottawa ankle rules for use of radiography in acute ankle injuries. Multicentre Ankle Rule Study Group. *BMJ* 1995;311:594-597. **(Multicenter, prospective, case-control; 12,777 patients)**
 89. Verma S, Hamilton K, Hawkins HH, et al. Clinical application of the Ottawa ankle rules for the use of radiography in acute ankle injuries: an independent site assessment. *Am J Roentgenol* 1997;169:825-827. **(Prospective validation; 926 patients aged 18-55 years)**
 90. Auleley GR, Ravaut P, Giraudeau B, et al. Implementation of the Ottawa ankle rules in France. A multicenter randomized controlled trial. *JAMA* 1997;277:1935-1939. **(Case-control, randomized; 1911 patients aged 18 years or older)**
 91. Leddy JJ, Smolinski RJ, Lawrence J, et al. Prospective evaluation of the Ottawa ankle rules in a university sports medicine center, with a modification to increase specificity for identifying malleolar fractures. *Am J Sports Med* 1998;26:158-165. **(Prospective validation; 132 children and adults aged 12-68 years)**
 92. Tay SY, Thoo FL, Sitoh YY, et al. The Ottawa Ankle Rules in Asia: validating a clinical decision rule for requesting X-rays in twisting ankle and foot injuries. *J Emerg Med* 1999 Nov-Dec;17(6):945-947. **(494 patients)**
 - 93.* Verbeek PR, Stiell IG, Hebert G, et al. Ankle radiograph utilization after learning a decision rule: a 12-month follow-up. *Acad Emerg Med* 1997 Aug;4(8):776-779. **(Follow-up study; 1884 patients)**
 - 94.* Wilson DE, Noseworthy TW, Rowe BH, et al. Evaluation of patient satisfaction and outcomes after assessment for acute ankle injuries. *Am J Emerg Med* 2002 Jan;20(1):18-22. **(Multicenter study)**
 95. Wilson FC. Fractures and dislocations of the ankle. In: Rockwood CA, Green DP, eds. *Rockwood and Green's Fractures in Adults*. Philadelphia: JB Lippincott; 1975:1665-1701. **(Textbook chapter)**
 96. Chapman MW. Fractures and fracture-dislocations of the ankle. In: Mann RA, Coughlin MJ, eds. *Surgery of the Foot and Ankle*. St. Louis, MO: CV Mosby; 1993:1439-1464. **(Textbook chapter)**
 97. Weber MJ. Ankle fractures and dislocations. In: Chapman MW, ed. *Operative Orthopedics*. Philadelphia: JB Lippincott;

- 1993:731-745. **(Textbook chapter)**
98. Senall JA, Kile TA. Stress radiography. *Foot Ankle Clin* 2000 Mar;5(1):165-184. **(Review; 27 references)**
 99. Harper MC, Keller TS. A radiographic evaluation of the tibiofibular syndesmosis. *Foot Ankle* 1989;10:156-160. **(Comparative; 12 cadavers)**
 100. Clanton TO, Porter DA. Primary care of foot and ankle injuries in the athlete. *Clin Sports Med* 1997;16:435-466. **(Review)**
 - 101.*Clark TW, Janzen DL, Ho K, et al. Detection of radiographically occult ankle fractures following acute trauma: positive predictive value of an ankle effusion. *AJR Am J Roentgenol* 1995;164:1185-1189. **(Prospective; 33 patients)**
 102. Clark TW, Janzen DL, Logan PM, et al. Improving the detection of radiographically occult ankle fractures: positive predictive value of an ankle joint effusion. *Clin Radiol* 1996;51:632-636. **(Prospective; 26 patients)**
 103. Danis R, ed. *Les Fractures Malléolaires. Théorie et Pratique de L'osteosynthèse*. Paris: Masson et Cie; 1949:133-165.
 104. Cox JS, Hewes TF. "Normal" talar tilt angle. *Clin Orthop* 1979;140:37-41. **(Prospective; 202 midshipmen)**
 105. Niedermann B, Andersen A, Bryde-Andersen S, et al. Rupture of the lateral ligaments of the ankle: operation or plaster cast? A prospective study. *Acta Orthop Scand* 1981;52:579-587. **(Prospective; 444 patients)**
 106. Smith RW, Reischl S. Treatment of ankle sprains in young athletes. *Am J Sports Med* 1986;14:465-471. **(Review)**
 107. Dupont M, Beliveau P, Theriault G. The efficacy of antiinflammatory medication in the treatment of the acutely sprained ankle. *Am J Sports Med* 1987;15:41-45. **(Prospective, placebo-controlled, double-blind; 61 patients aged 16 years or older)**
 108. Trevino SG, Davis P, Hecht PJ. Management of acute and chronic lateral ligament injuries of the ankle. *Orthop Clin North Am* 1994;25:1-16. **(Review)**
 109. Harris CR. Ankle injuries. In: Ruiz E, Cicero JJ, eds. *Emergency Management of Skeletal Injuries*. St. Louis, MO: CV Mosby; 1995:517-540. **(Textbook chapter)**
 110. Michelson JD. Current concepts review: fractures about the ankle. *J Bone Joint Surg Am* 1995;77A:142-152. **(Review)**
 111. Brostrom L. Sprained ankles. I. Anatomic lesions in recent sprains. *Acta Chir Scand* 1964;128:483-495. **(Observational; 105 surgically explored ankle sprains)**
 112. Porter DA, Villareal R, May C, et al. Functional bracing with a half-cast. *Foot Ankle Int* 1996 Oct;17(10):644-645.
 113. Boytim MJ, Fischer DA, Neumann L. Syndesmotic ankle sprains. *Am J Sports Med* 1991;19:294-298. **(Retrospective, comparative; 15 syndesmosis sprains and 28 lateral sprains in professional football players)**
 - 114.*Eiff MP, Smith AT, Smith GE. Early mobilization versus immobilization in the treatment of lateral ankle sprains. *Am J Sports Med* 1994 Jan-Feb;22(1):83-88. **(Randomized controlled trial; 82 patients)**
 - 115.*Kerkhoffs GM, Rowe BH, Assendelft WJ, et al. Immobilisation for acute ankle sprain. A systematic review. *Arch Orthop Trauma Surg* 2001 Sep;121(8):462-471. **(Review; 97 references)**
 116. Leanderson J, Wredmark T. Treatment of acute ankle sprain. Comparison of a semi-rigid ankle brace and compression bandage in 73 patients. *Acta Orthop Scand* 1995 Dec;66(6):529-531. **(Randomized controlled trial; 73 patients)**
 117. Dettori JR, Pearson BD, Basmania CJ, et al. Early ankle mobilization, Part I: The immediate effect on acute, lateral ankle sprains (a randomized clinical trial). *Mil Med* 1994 Jan;159(1):15-20. **(Randomized controlled trial; 64 patients)**
 118. Simpson KJ, Cravens S, Higbie E, et al. A comparison of the Sport Stirrup, Malleoloc, and Swede-O ankle orthoses for the foot-ankle kinematics of a rapid lateral movement. *Int J Sports Med* 1999 Aug;20(6):396-402. **(Comparative; 19 patients)**
 119. Leanderson J, Bergqvist M, Rolf C, et al. Early influence of an ankle sprain on objective measures of ankle joint function. A prospective randomised study of ankle brace treatment. *Knee Surg Sports Traumatol Arthrosc* 1999;7(1):51-58. **(Randomized, controlled trial; 73 patients)**
 120. Hamilton WC. Injuries of the ankle and foot. *Emerg Med Clin North Am* 1984;2:361-389. **(Review)**
 121. Beris AE, Kabbani KT, Xenakis TA, et al. Surgical treatment of malleolar fractures: a review of 144 patients. *Clin Orthop* 1997;341:90-98. **(Prospective, cohort; 144 surgical patients aged 17 years or older)**
 122. Phillips WA, Schwartz HS, Keller CS, et al. A prospective, randomized study of the management of severe ankle fractures. *J Bone Joint Surg Am* 1985;67A:67-78. **(Prospective, randomized, cohort; 138 patients)**
 - 123.*Halvorson G, Iserson KV. Comparison of four ankle splint designs. *Ann Emerg Med* 1987;16:1249-1252. **(Prospective, comparative; 6 subjects each testing 4 splint designs)**
 124. Chudnofsky CR. Splinting techniques. In: Roberts JR, Hedges JR, eds. *Clinical Procedures in Emergency Medicine*. Philadelphia: WB Saunders Company; 1998:852-873. **(Textbook chapter)**
 125. McBride KL. Validation of the Ottawa ankle rules. Experience at a community hospital. *Can Fam Physician* 1997;43:459-465. **(Prospective validation; 259 adults and 37 children)**
 126. Chande VT. Decision rules for roentgenography of children with acute ankle injuries. *Arch Pediatr Adolesc Med* 1995;149:255-258. **(Prospective; 71 children)**
 127. Libetta C, Burke D, Brennan P, et al. Validation of the Ottawa ankle rules in children. *J Accid Emerg Med* 1999;16:342-344. **(Prospective validation; 761 children 1 year or older)**
 - 128.*Plint AC, Bulloch B, Osmond MH, et al. Validation of the Ottawa ankle rules in children with ankle injuries. *Acad Emerg Med* 1999;6:1005-1009. **(Prospective validation; 670 children aged 2-6 years)**
 129. Ho K, Connell DG, Janzen DL, et al. Using tomography to diagnose occult ankle fractures. *Ann Emerg Med* 1996;27:600-605. **(Prospective, cohort; 34 patients)**
 130. Schneck CD, Mesgarzdeh M, Bonakdarpour A. MR imaging of the most commonly injured ankle ligaments. Part 2: ligament injuries. *Radiology* 1992;184:507-518.
 131. De Lacey G, Bradbrooke S. Rationalizing requests for x-ray examination of acute ankle injuries. *Br Med J* 1979;1:1597-1598. **(Retrospective; 193 patients)**
 - 132.*Allerston J, Justham D. A case-control study of the transit times through an Accident and Emergency department of ankle injured patients assessed using the Ottawa Ankle Rules. *Accid Emerg Nurs* 2000;8:148-154. **(Retrospective, case-control; 183 patients)**
 - 133.*Salt P, Clancy M. Implementation of the Ottawa Ankle Rules by nurses working in an accident and emergency department. *J Accid Emerg Med* 1997 Nov;14(6):363-365. **(Prospective, observational; 324 patients)**

Physician CME Questions

- 65. Which of the following is the most commonly injured soft-tissue structure(s) of the ankle?**
- Lateral collateral ligaments
 - Medial collateral ligaments
 - Inferior tibiofibular ligaments
 - Achilles tendon
- 66. All of the following terms describe a motion of the talus within the mortise except:**
- adduction.
 - external rotation.
 - supination.
 - plantar flexion.
- 67. According to the Lauge-Hansen classification scheme, the mechanism of injury that accounts for the greatest number of ankle fractures is:**
- supination-adduction (inversion).
 - pronation-abduction (eversion).
 - supination-external rotation.
 - pronation-external rotation.
- 68. Which of the following describes an unstable injury pattern?**
- Lateral ligament tear with lateral malleolar avulsion fracture
 - Lateral ligament tear with medial malleolar avulsion fracture
 - Medial ligament rupture
 - Medial malleolar fracture
- 69. Each of the following ligaments are part of the ankle syndesmosis except:**
- Anterior inferior tibiofibular ligament (AITFL)
 - Posterior inferior tibiofibular ligament (PITFL)
 - Interosseous ligament (IOL)
 - Calcaneofibular ligament (CFL)
- 70. Nonunion and chronic disability may result from inadequate immobilization of:**
- lateral malleolar avulsion fractures.
 - avulsion fractures of the tuberosity of the fifth metatarsal (pseudo-Jones).
 - fifth metatarsal shaft fractures (Jones).
 - lateral ligament tears with lateral malleolar avulsion fractures.
- 71. Widening of the medial clear space on ankle radiographs suggests injury to each of the following structures except:**
- lateral ligament complex.
 - deltoid ligament.
 - anterior inferior tibiofibular ligament (AITFL).
 - posterior inferior tibiofibular ligament (PITFL).
- 72. Pain at the ankle during squeeze testing is suggestive of injury to which structure(s)?**
- Medial collateral ligaments
 - Inferior tibiofibular ligaments
 - Lateral collateral ligaments
 - Peroneal tendons
- 73. According to the Danis-Weber classification scheme, which of the following injuries is likely to require operative management?**
- Pronation-abduction grade 1—oblique medial malleolar fracture below the mortise
 - Pronation-external rotation grade 3—fibular fracture above the mortise and disruption of the syndesmosis
 - Supination-external rotation grade 2—spiral fracture of the lateral malleolus at the level of the mortise and intact syndesmosis
 - Supination-adduction grade 1—oblique lateral malleolar fracture below the mortise
- 74. An emergency physician who applies the Ottawa Ankle Rules correctly would send which of the following ambulatory patients with a chief complaint of “ankle pain” for x-ray?**
- A 40-year-old male with tenderness upon palpation of the posterior edge of the medial malleolar tip
 - A 25-year-old female with edema, ecchymosis, and tenderness just anterior to the lateral malleolus
 - A 60-year-old male with lateral edema, ecchymosis, and a positive anterior drawer test
 - A 16-year-old male with posterior ankle tenderness and a positive Thompson test
- 75. Characteristics of a Maisonneuve fracture include all of the following except:**
- It occurs in the setting of forceful external rotation.
 - It is frequently associated with medial ligament and/or syndesmosis disruption.
 - It is highly unstable.
 - The diagnosis is readily made on routine ankle x-ray series.
- 76. All of the following fractures warrant orthopedic consultation in the ED except:**
- unimalleolar fracture.
 - bimalleolar fracture.
 - trimalleolar fracture.
 - triplane fracture.
- 77. The best test for Achilles tendon rupture is:**
- ability to pronate the foot.
 - ability to dorsiflex the foot.
 - the Thompson squeeze test.
 - the “wiggle test.”

78. All of the following provide rigid immobilization for high-grade sprains and fractures except:

- a. posterior splint.
- b. anterior and posterior splint.
- c. sugar-tong splint.
- d. Jones compression dressing.

79. On a normal AP ankle x-ray, the amount of tibiofibular overlap should be at least:

- a. 2 mm.
- b. 4 mm.
- c. 6 mm.
- d. 8 mm.

80. The Lauge-Hansen classification of ankle fractures is based on:

- a. the anatomic location of the fibular fracture with respect to the mortise.
- b. the mechanism of injury.
- c. the degree of articular involvement.
- d. the presence or absence of syndesmotic disruption.

Class Of Evidence Definitions

Each action in the clinical pathways section of *Emergency Medicine Practice* receives an alpha-numerical score based on the following definitions.

Class I

- Always acceptable, safe
- Definitely useful
- Proven in both efficacy and effectiveness

Level of Evidence:

- One or more large prospective studies are present (with rare exceptions)
- High-quality meta-analyses
- Study results consistently positive and compelling

Class II

- Safe, acceptable
- Probably useful

Level of Evidence:

- Generally higher levels of evidence
- Non-randomized or retrospective studies: historic, cohort, or case-control studies
- Less robust RCTs
- Results consistently positive

Class III

- May be acceptable
- Possibly useful
- Considered optional or alternative treatments

Level of Evidence:

- Generally lower or intermediate levels of evidence

- Case series, animal studies, consensus panels
- Occasionally positive results

Indeterminate

- Continuing area of research
- No recommendations until further research

Level of Evidence:

- Evidence not available
- Higher studies in progress
- Results inconsistent, contradictory
- Results not compelling

Significantly modified from: The Emergency Cardiovascular Care Committees of the American Heart Association and representatives from the resuscitation councils of ILCOR: How to Develop Evidence-Based Guidelines for Emergency Cardiac Care: Quality of Evidence and Classes of Recommendations; also: Anonymous. Guidelines for cardiopulmonary resuscitation and emergency cardiac care. Emergency Cardiac Care Committee and Subcommittees, American Heart Association. Part IX. Ensuring effectiveness of community-wide emergency cardiac care. *JAMA* 1992;268(16):2289-2295.

Emergency Medicine Practice is not affiliated with any pharmaceutical firm or medical device manufacturer.

Physician CME Information

This CME enduring material is sponsored by Mount Sinai School of Medicine and has been planned and implemented in accordance with the Essentials and Standards of the Accreditation Council for Continuing Medical Education. Credit may be obtained by reading each issue and completing the post-tests administered in December and June.

Target Audience: This enduring material is designed for emergency medicine physicians.

Needs Assessment: The need for this educational activity was determined by a survey of medical staff, including the editorial board of this publication; review of morbidity and mortality data from the CDC, AHA, NCHS, and ACEP; and evaluation of prior activities for emergency physicians.

Date of Original Release: This issue of *Emergency Medicine Practice* was published May 1, 2002. This activity is eligible for CME credit through May 1, 2005. The latest review of this material was April 4, 2002.

Discussion of Investigational Information: As part of the newsletter, faculty may be presenting investigational information about pharmaceutical products that is outside Food and Drug Administration approved labeling. Information presented as part of this activity is intended solely as continuing medical education and is not intended to promote off-label use of any pharmaceutical product. *Disclosure of Off-Label Usage:* This issue of *Emergency Medicine Practice* discusses no off-label use of any pharmaceutical product.

Faculty Disclosure: In compliance with all ACCME Essentials, Standards, and Guidelines, all faculty for this CME activity were asked to complete a full disclosure statement. The information received is as follows: Dr. Wasserman, Dr. Hill, Dr. Burg, and Dr. Turturro report no significant financial interest or other relationship with the manufacturer(s) of any commercial product(s) discussed in this educational presentation.

Accreditation: Mount Sinai School of Medicine is accredited by the Accreditation Council for Continuing Medical Education to sponsor continuing medical education for physicians.

Credit Designation: Mount Sinai School of Medicine designates this educational activity for up to 4 hours of Category 1 credit toward the AMA Physician's Recognition Award. Each physician should claim only those hours of credit actually spent in the educational activity. *Emergency Medicine Practice* is approved by the American College of Emergency Physicians for 48 hours of ACEP Category 1 credit (per annual subscription).

Earning Credit: Two Convenient Methods

- **Print Subscription Semester Program:** Physicians with current and valid licenses in the United States who read all CME articles during each *Emergency Medicine Practice* six-month testing period, complete the post-test and the CME Evaluation Form distributed with the December and June issues, and return it according to the published instructions are eligible for up to 4 hours of Category 1 credit toward the AMA Physician's Recognition Award (PRA) for each issue. You must complete both the post-test and CME Evaluation Form to receive credit. Results will be kept confidential. CME certificates will be delivered to each participant scoring higher than 70%.
- **Online Single-Issue Program:** Physicians with current and valid licenses in the United States who read the *Emergency Medicine Practice* CME article and complete the post-test and CME Evaluation Form are eligible for up to 4 hours of Category 1 credit toward the AMA Physician's Recognition Award (PRA). You must complete both the post-test and CME Evaluation Form to receive credit. Results will be kept confidential. CME certificates may be printed directly from the Web site to each participant scoring higher than 70%.

Publisher: Robert Williford. **Vice President/General Manager:** Connie Austin. **Executive Editor:** Heidi Frost.

Direct all editorial or subscription-related questions to EB Practice, LLC:
1-800-249-5770 Fax: 770-500-1316
EB Practice, LLC / 305 Windlake Court / Alpharetta, GA 30022
E-mail: emp@empractice.net
Web Site: <http://www.empractice.net>

Emergency Medicine Practice (ISSN 1524-1971) is published monthly (12 times per year) by EB Practice, LLC, 305 Windlake Court, Alpharetta, GA 30022. Opinions expressed are not necessarily those of this publication. Mention of products or services does not constitute endorsement. This publication is intended as a general guide and is intended to supplement, rather than substitute, professional judgment. It covers a highly technical and complex subject and should not be used for making specific medical decisions. The materials contained herein are not intended to establish policy, procedure, or standard of care. *Emergency Medicine Practice* is a trademark of EB Practice, LLC. Copyright ©2002 EB Practice, LLC. All rights reserved. No part of this publication may be reproduced in any format without written consent of EB Practice, LLC. Subscription price: \$249, U.S. funds. (Call for international shipping prices.)